

Cover Photos: Julie Larsen Maher © WCS

Gross Necropsy Examination

AVIAN



About these training resources



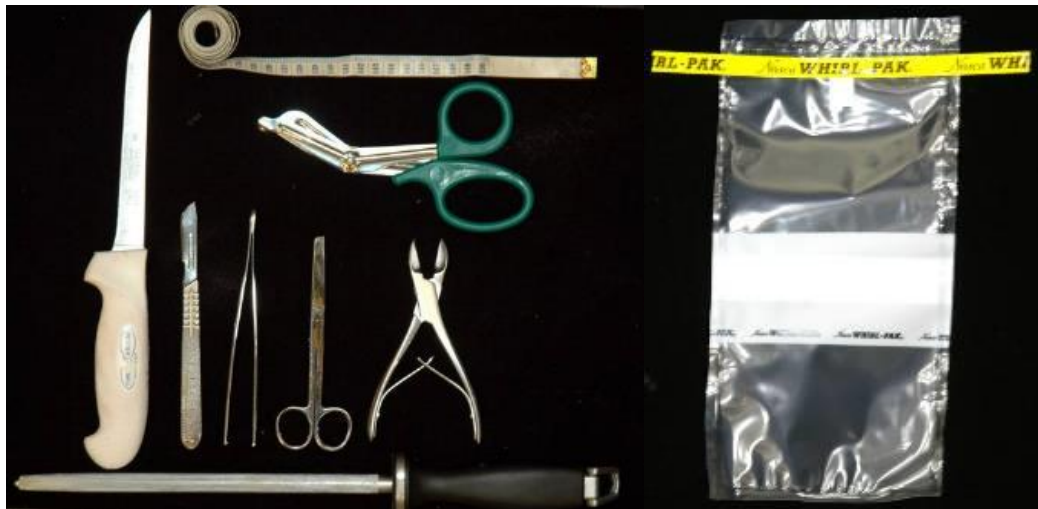This necropsy resource was created by the Wildlife Conservation Society's Zoological Health Program/Pathology Department at the Bronx Zoo in New York, NY, USA



This resource is being shared as part of the **WildHealthNet** initiative, which was funded by the Defense Threat Reduction Agency (DTRA) Biological Threat Reduction Program (BTRP) of the U.S. Department of Defense, and builds on the Wildlife Conservation Society Health Program's expertise in One Health policy, pathogen surveillance (USAID's PREDICT), and wildlife surveillance activities in Southeast Asia (EU LACANET).

Preparation

- PPE
- Documentation - necropsy form
- Camera
- Tools/equipment
- Sample collection containers
- Personnel – clean vs. contaminated



Tissue examination and collection checklist

INTERNAL EXAMINATION

Musculoskeletal system (e.g. fractures, dislocations, arthritis, joint infection, muscle atrophy, trauma):

Body cavity

GROSS NECROPSY EXAMINATION

Use the spaces below to record the size, shape, color, consistency/texture of the organs examined and the location, number and distribution of any abnormal findings.

Take (e.g.)

If the exam

Wild Health Net

NECROPSY FORM

Prosector: _____ Organization: _____

Date recorder: _____ Organization: _____

EVENT INFORMATION

Event ID: _____

Location of event: _____

Location of necropsy: _____

Necropsy date: _____ Necropsy time: _____

Storage (prior to necropsy): Ambient Refrigerated On ice Frozen

Multiple animal deaths? Yes No Number of animals (if yes): _____

ANIMAL INFORMATION

Animal ID: _____

Location of death: _____ GPS Location: _____

Date of death: _____ Time of death: _____

Carcass recovery date: _____ Carcass recovery time: _____

Carcass condition: Fresh Early Advanced Completely decomposed

Species: _____

Sex: _____ Male _____ Female _____ Undetermined

Age: Neonate (days) Juvenile (weeks/months) Adult Geriatric

HISTORY

Suspected cause of death (circle)

Euthanasia Trauma Poison/Toxin

Infectious disease Other Unknown

Hunting/POaching: Snare Gunshot

Known history: _____



10% buffered formalin

100 ml formalin (38-40% formaldehyde)

900 ml distilled water

4 g sodium chloride (table salt) [OR 4.5 g sodium phosphate (monobasic) and 3.6 g sodium hydroxide]

<http://www.vetmed.ucdavis.edu/whc/pdfs/necropsy.pdf>

10:1

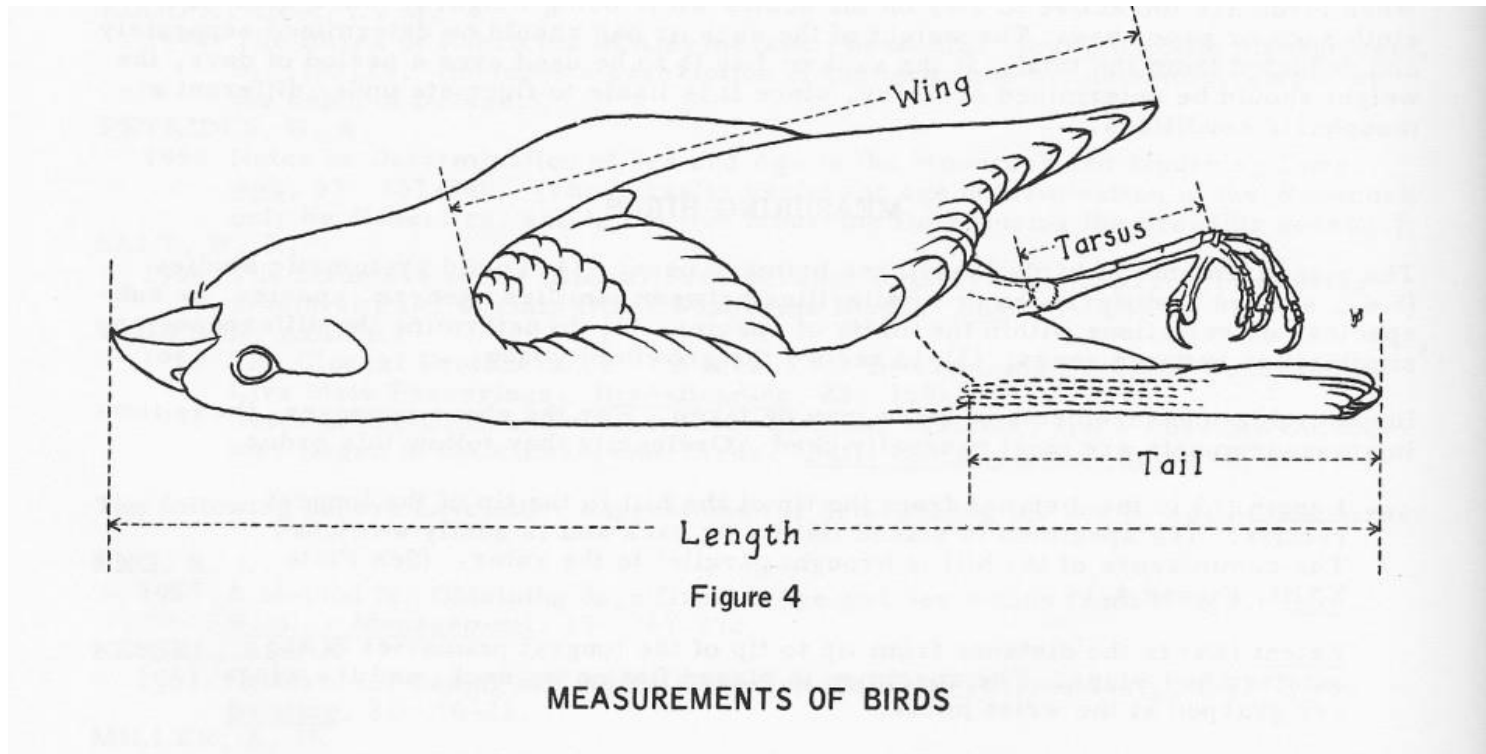
Formalin:Tissue ratio

External Examination



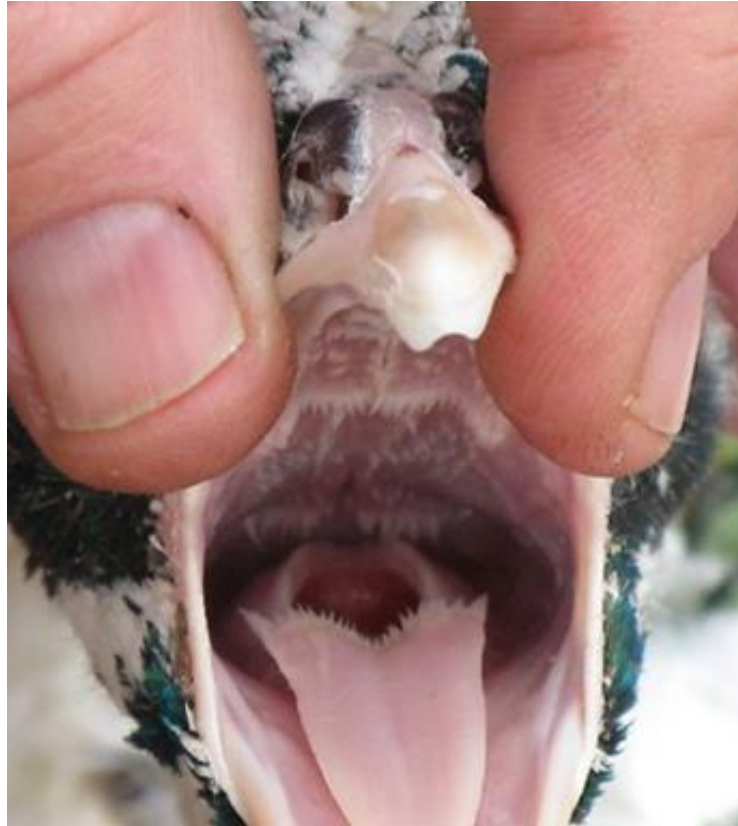
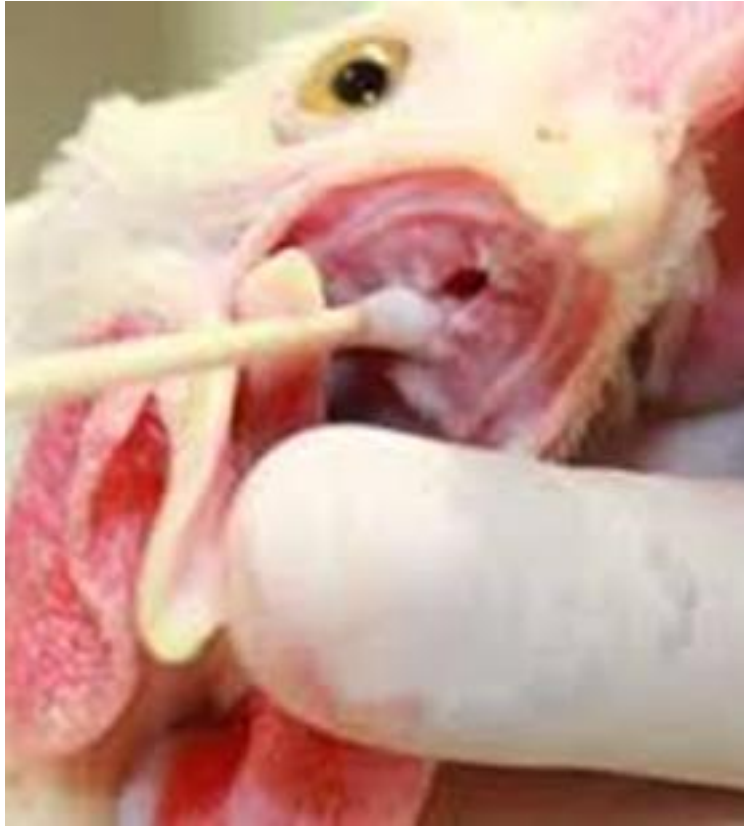- **Weight**
- **Skin, feathers, wings**
- **Eyes, ears, nares**
- **Beak, oral cavity, choana**
- **Mucous membranes**
- **Vent, cloaca, uropygial gland**
- **Feet, nails**
- **Bones, musculature**
- **Age category**
- **Body Condition**
- **Post-mortem condition**
- **External measurements**

External Measurements



- Length
- Wing
- Tail

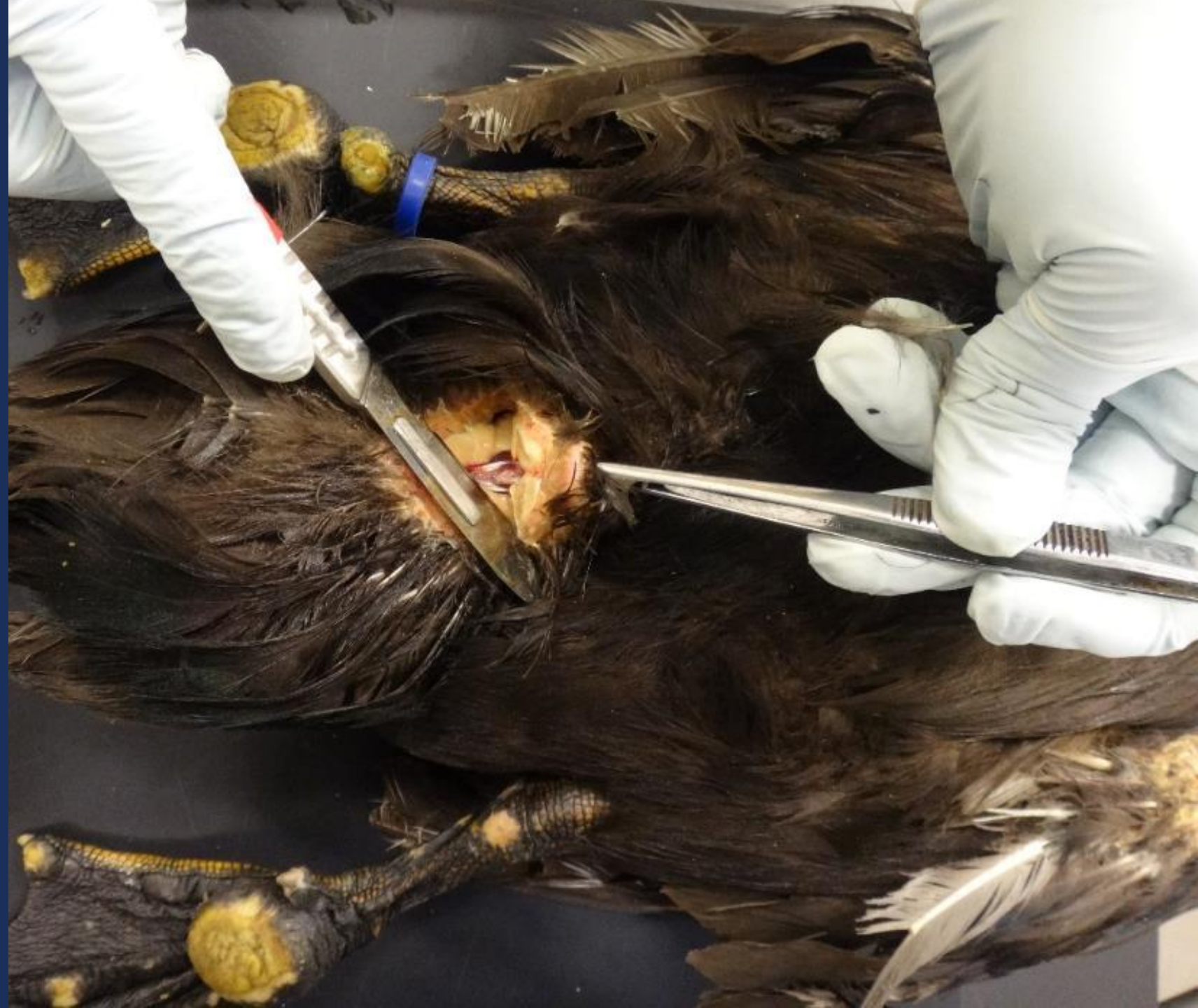<https://entropymag.org/the-birds-bird-erasures>



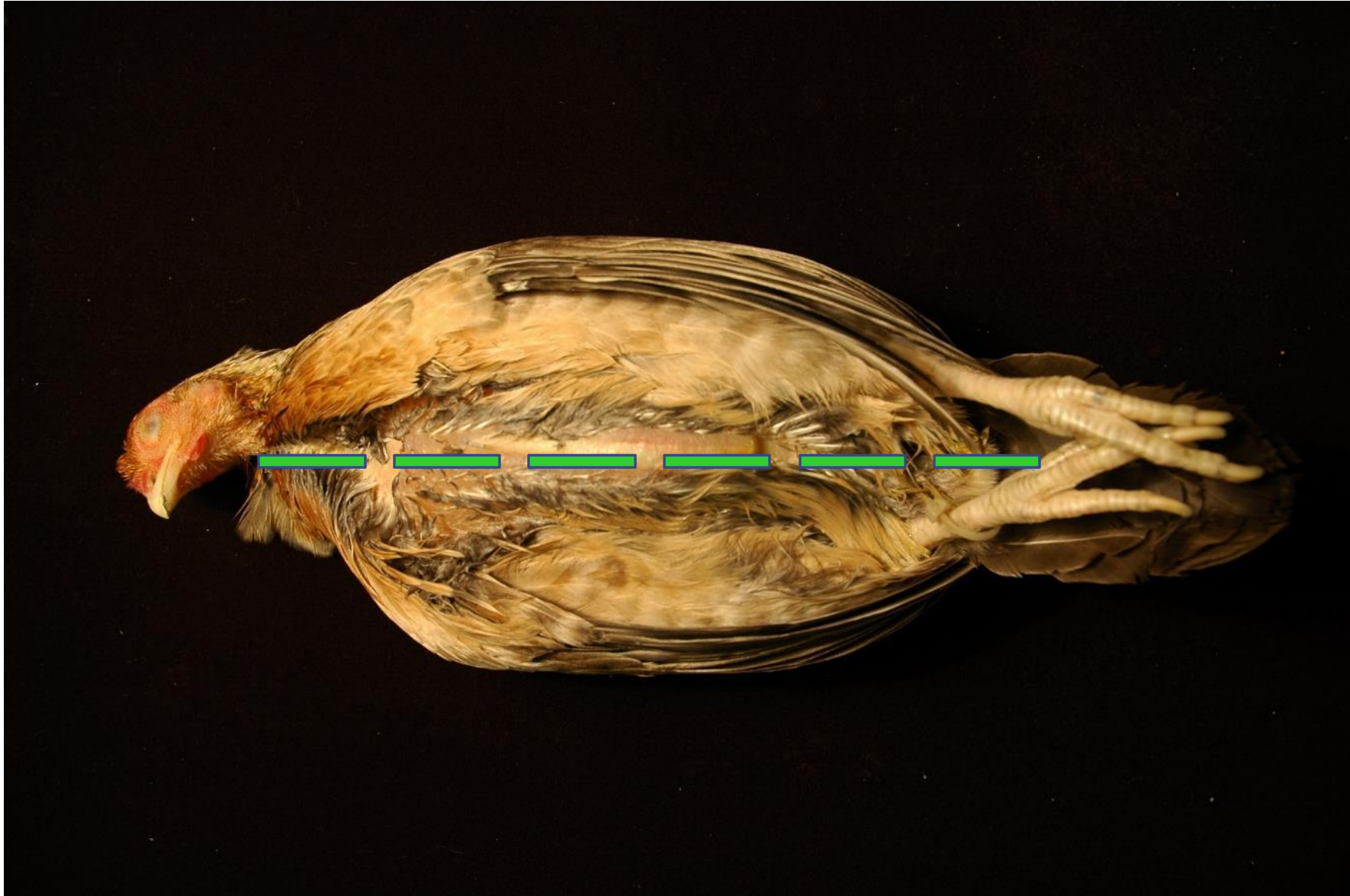Collect oral/cloacal swabs in VTM or RNA later

Examine, collect
uropygial gland

Note: The uropygial gland is on
the back near the base of the tail



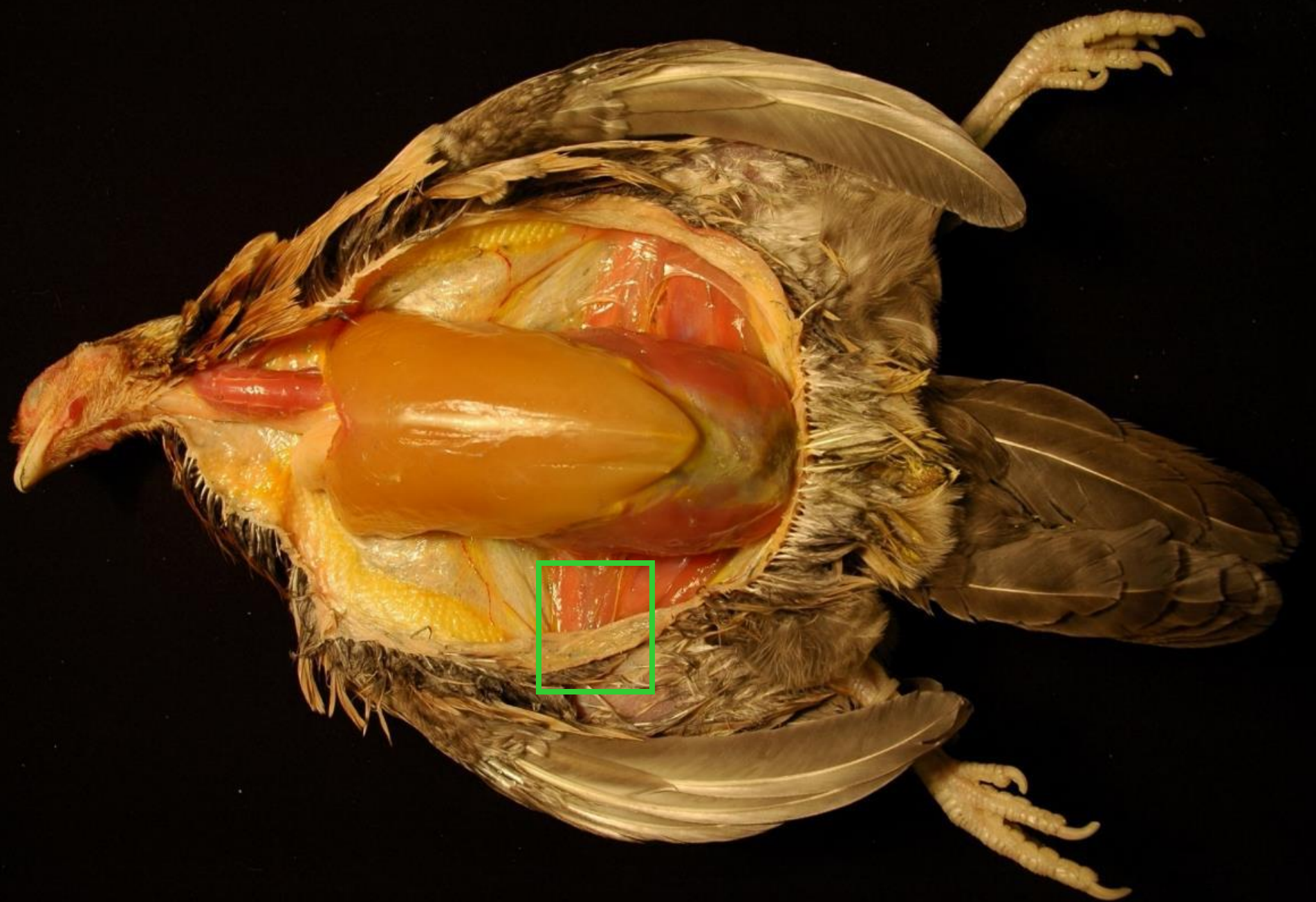
Open body with ventral midline incision from beak to vent



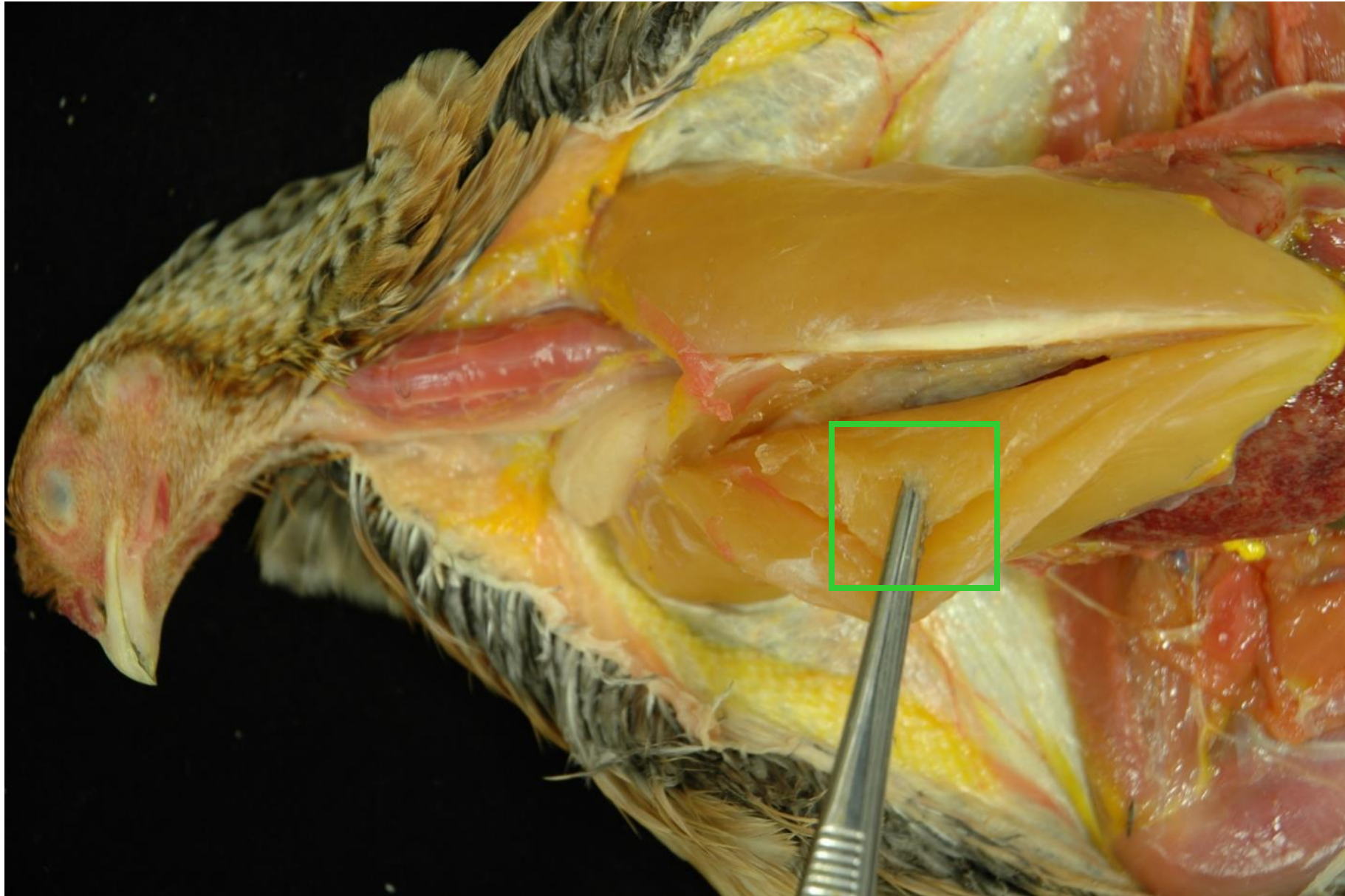
Reflect skin

Note adipose,
level of
pectoral
muscles

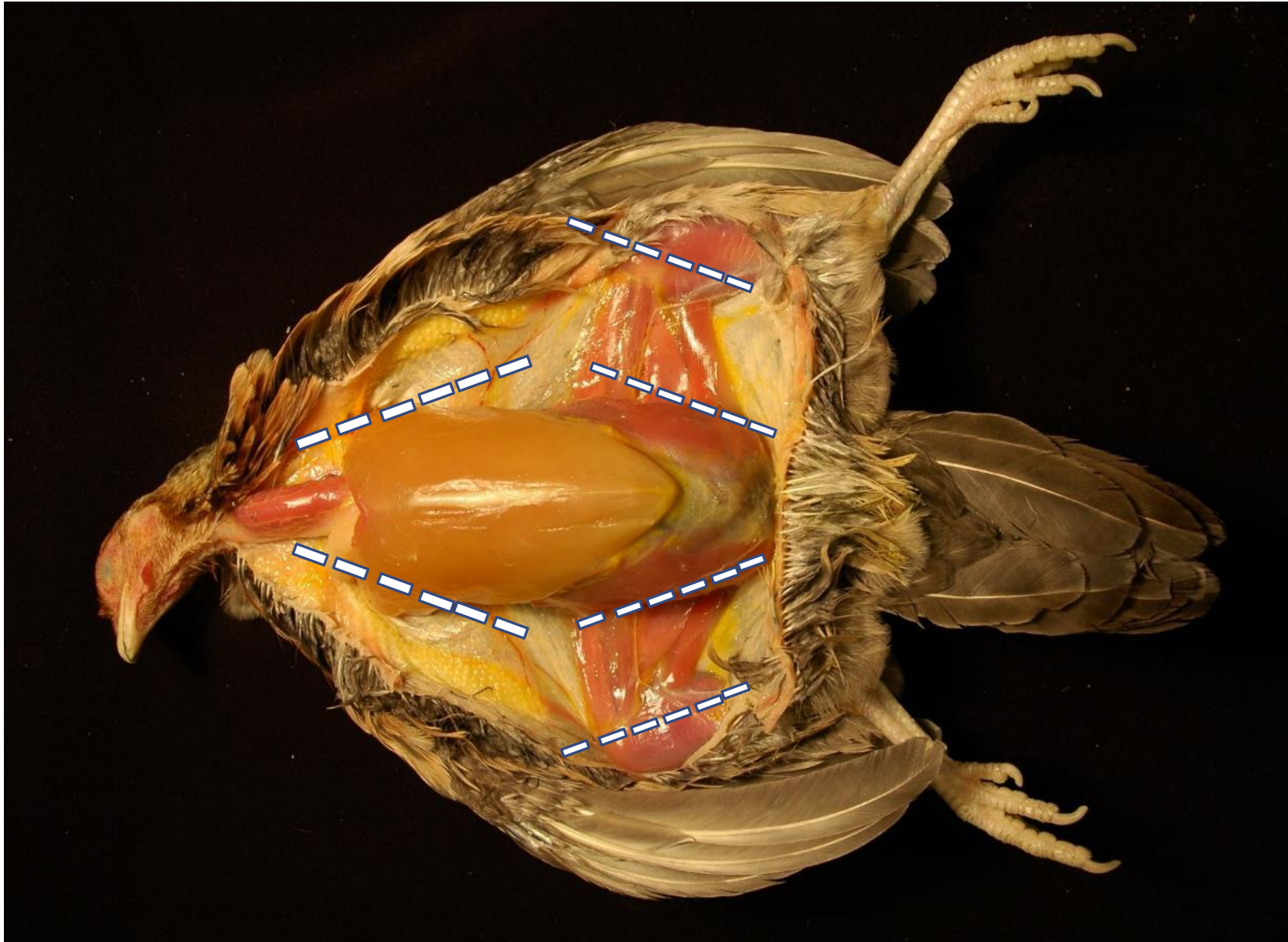
Collect skin
sample



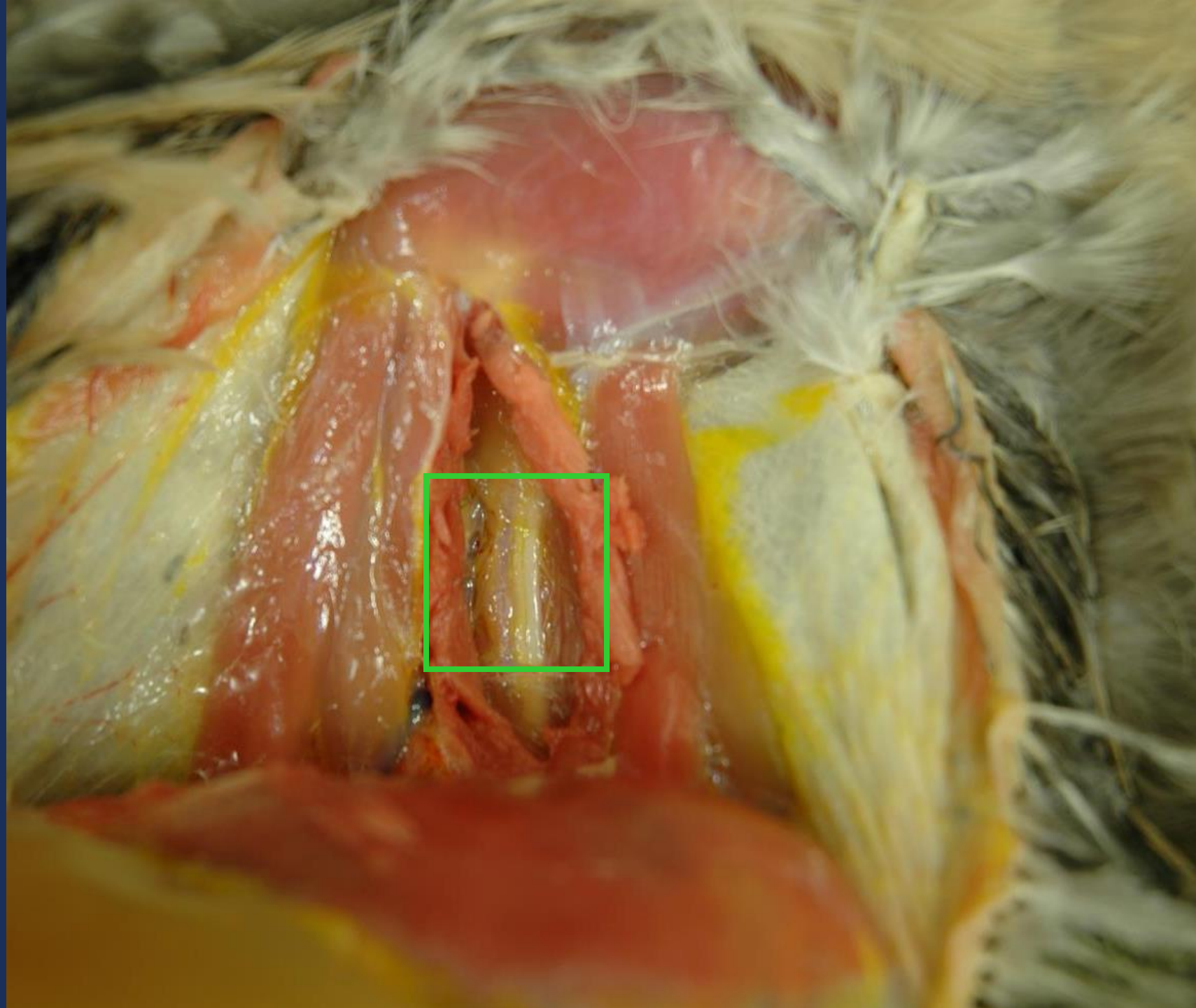
Examine, collect sample of pectoral muscle



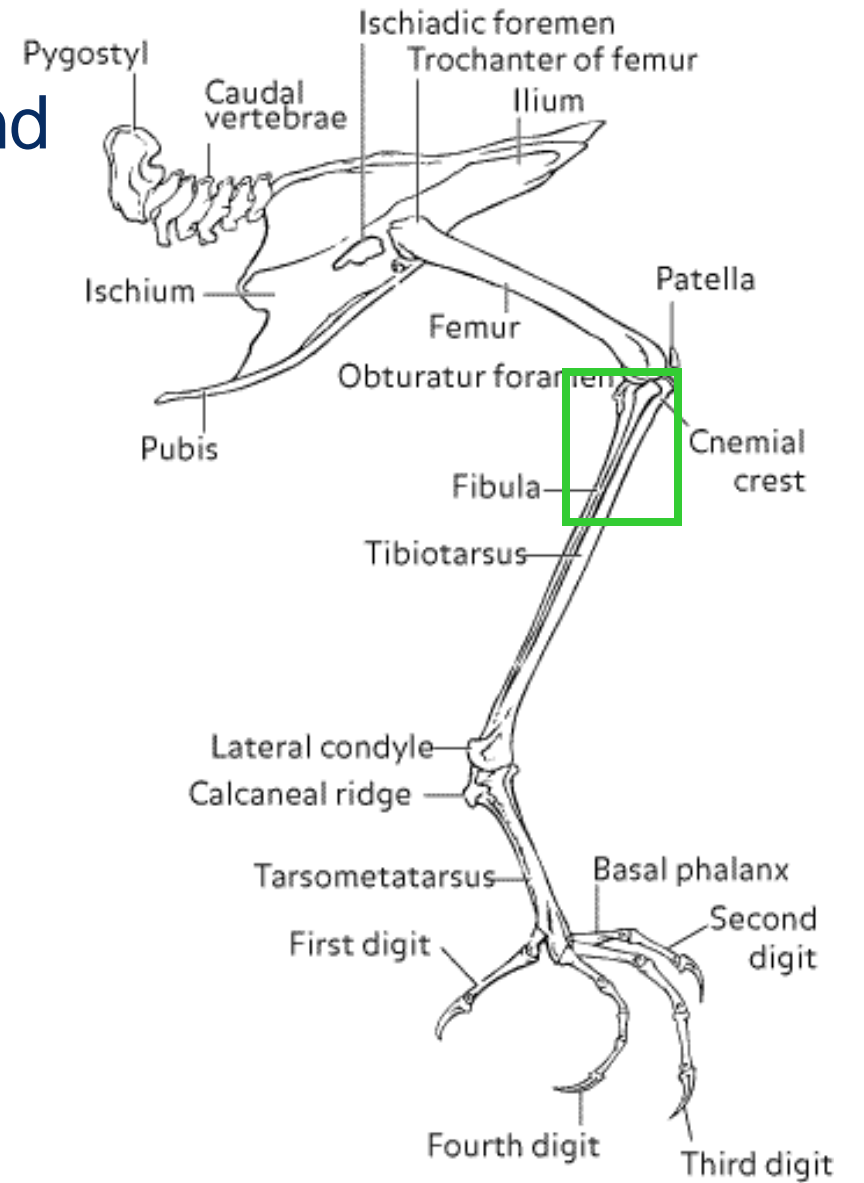
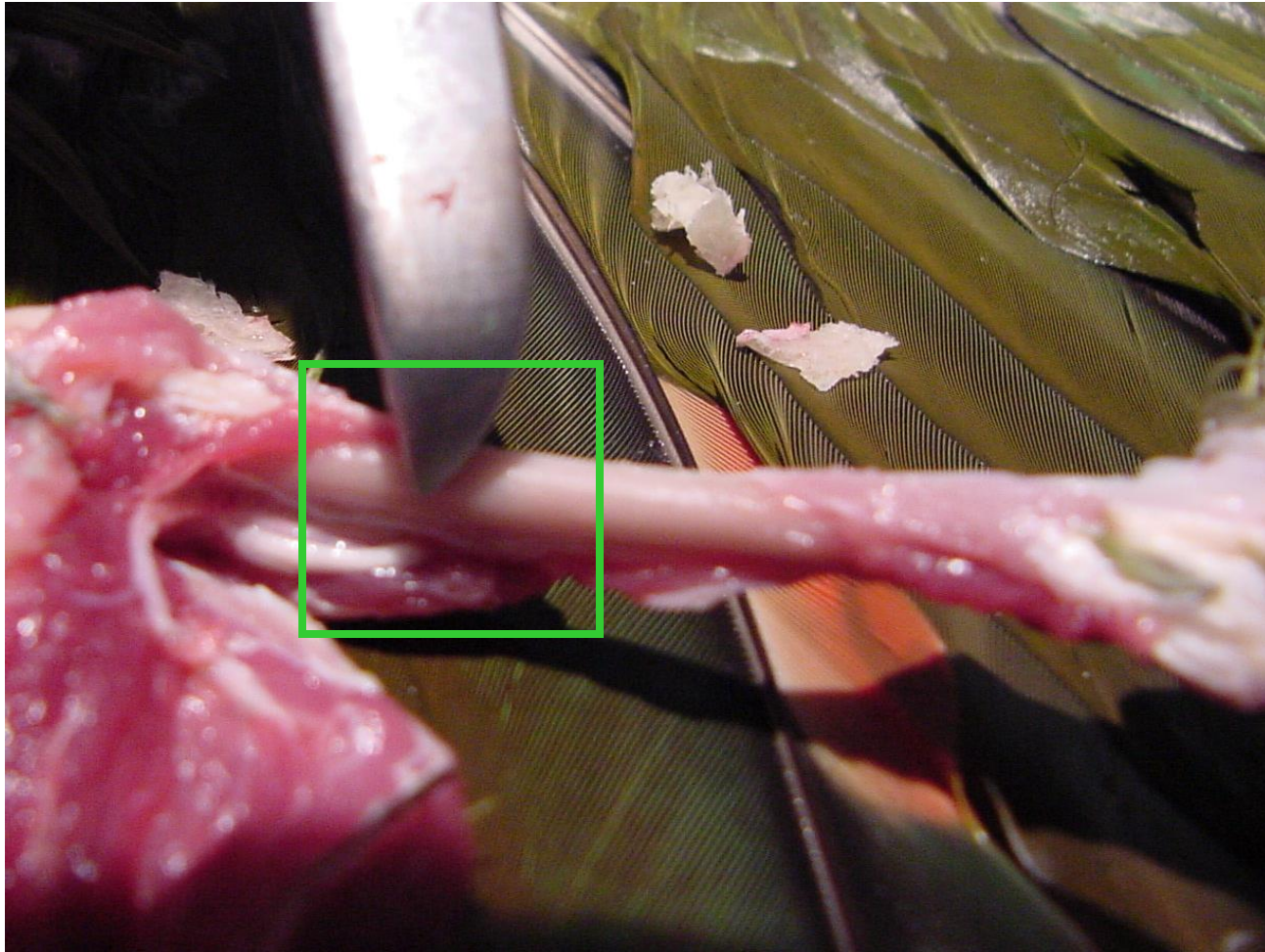
Open, examine shoulder, hip, knee joints



- Expose, examine leg muscle, sciatic nerve
- Collect samples of each



Expose, examine, fracture tibiotalar bone
Examine, collect bone marrow from proximal end



JR White Angell Memorial Hospital 2003

CHECKPOINT 1

External examination

- Body condition
- Postmortem condition
- Lesions
- Samples

Internal exam – part 1

- Subcutis, adipose, joints, skeletal muscle
- Sciatic nerve
- Bone marrow
- Lesions
- Samples



Open the coelom with
T-shaped cut

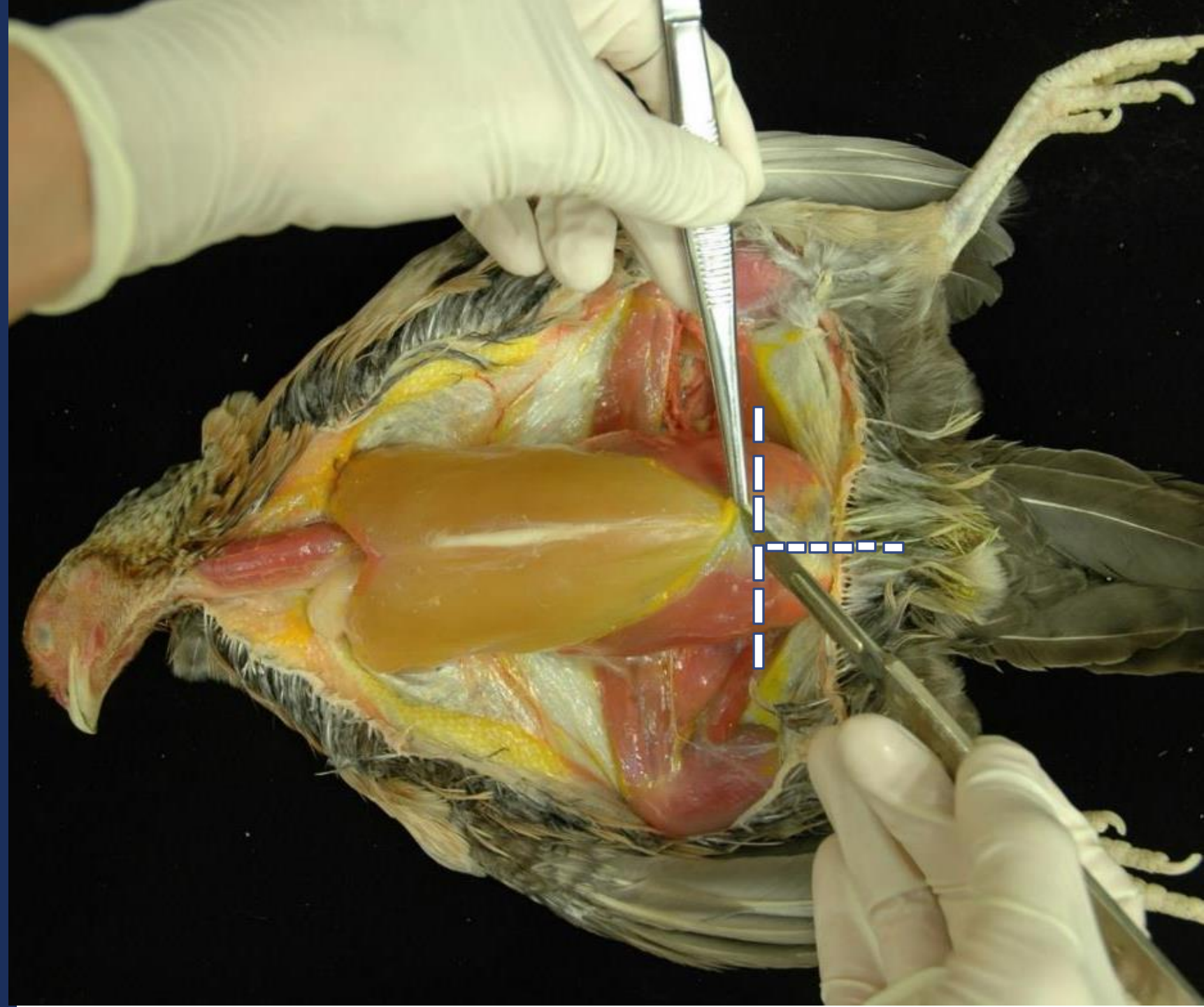
Reflect body wall

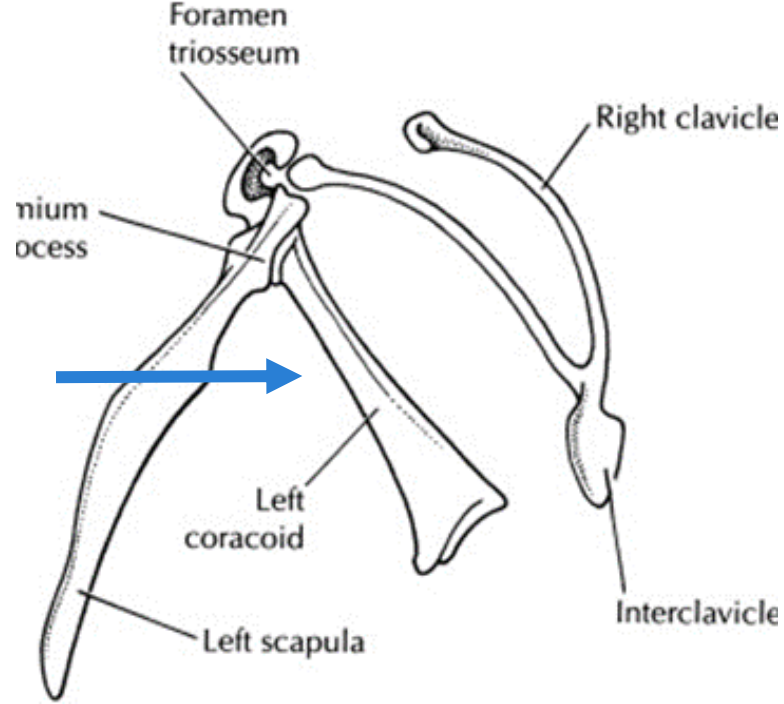
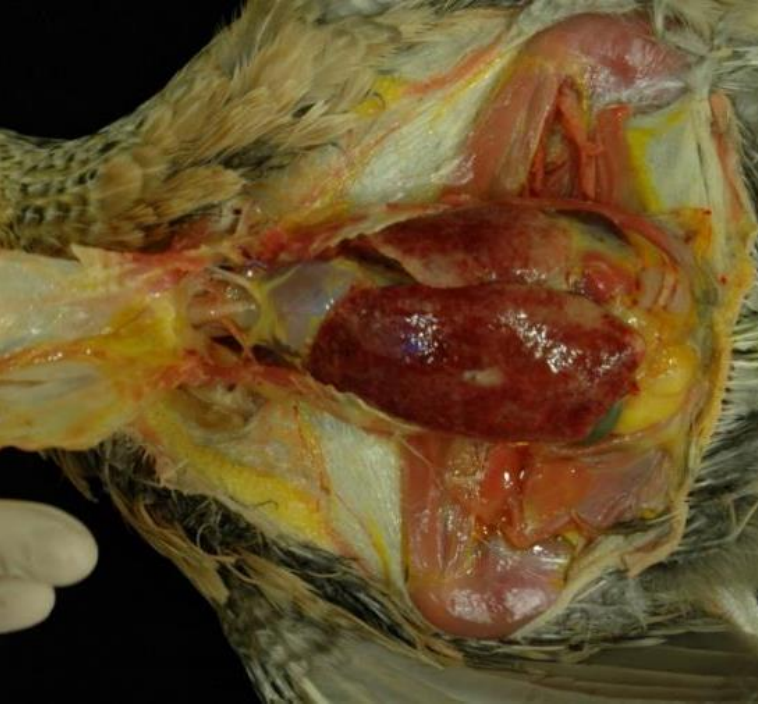Assess, collect
abnormal fluid

Note fat stores

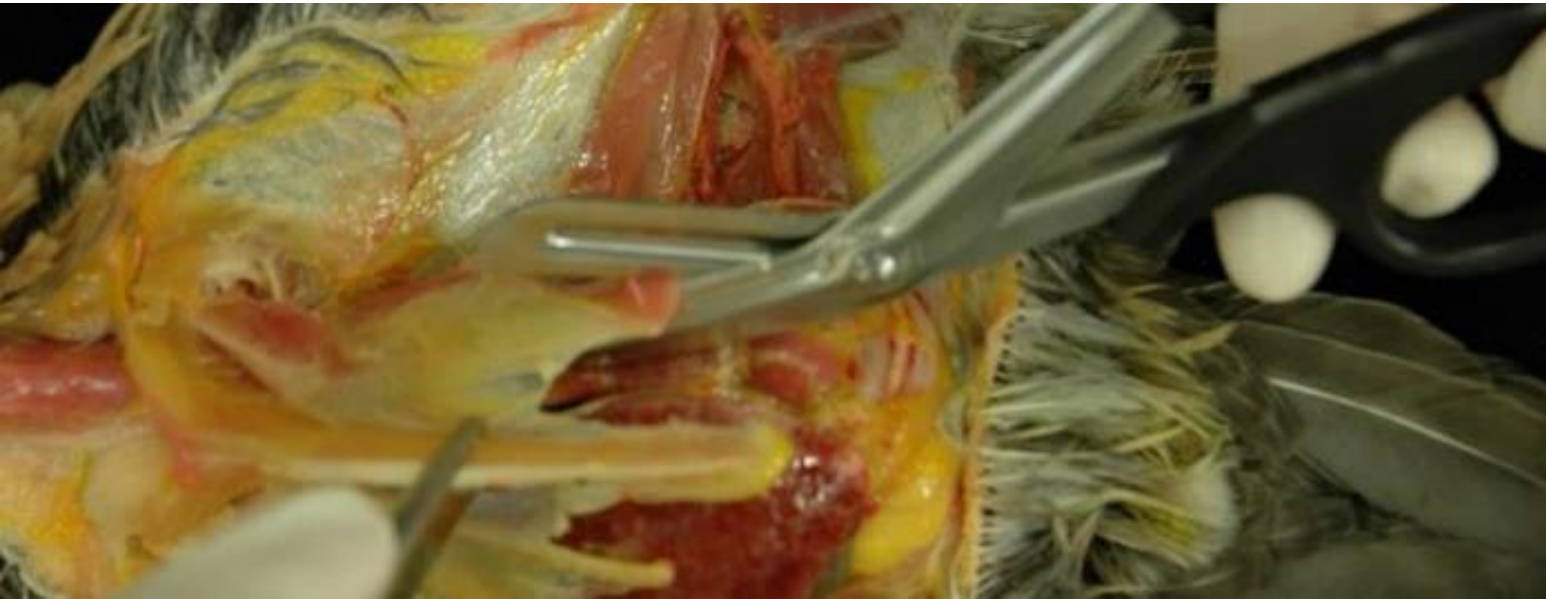
Examine air sacs

Note: handle tissues to minimize
contamination of internal organs



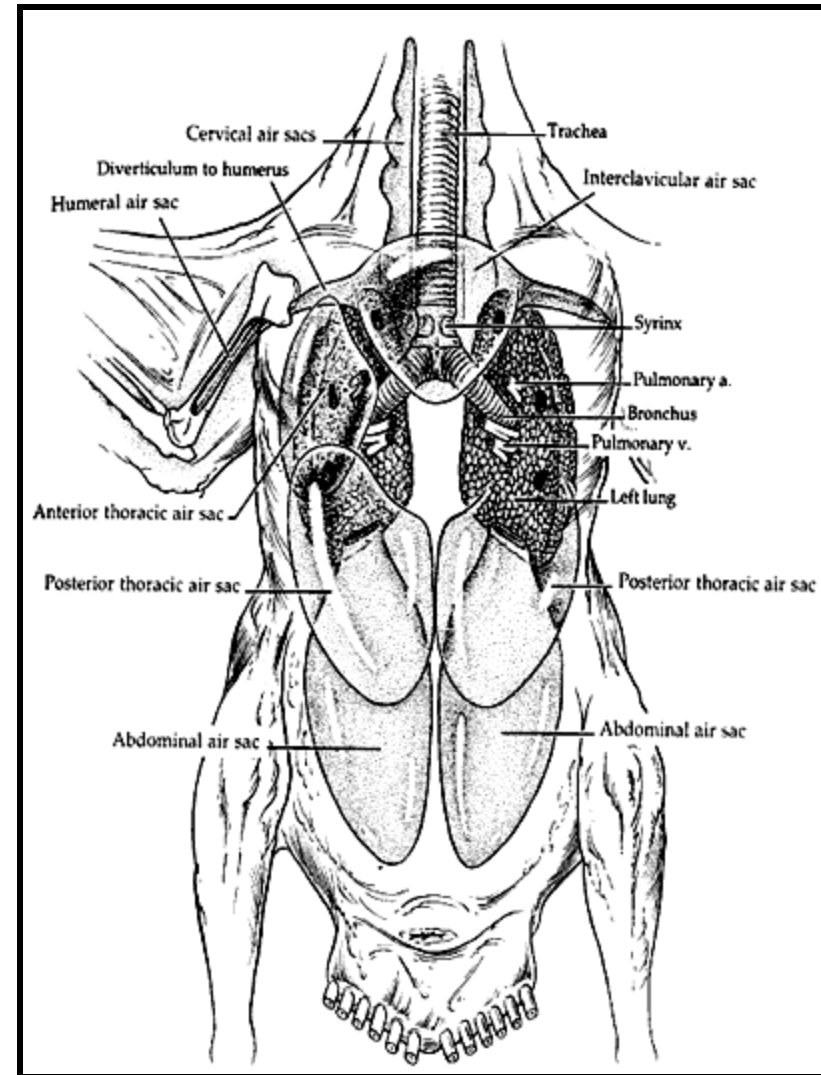
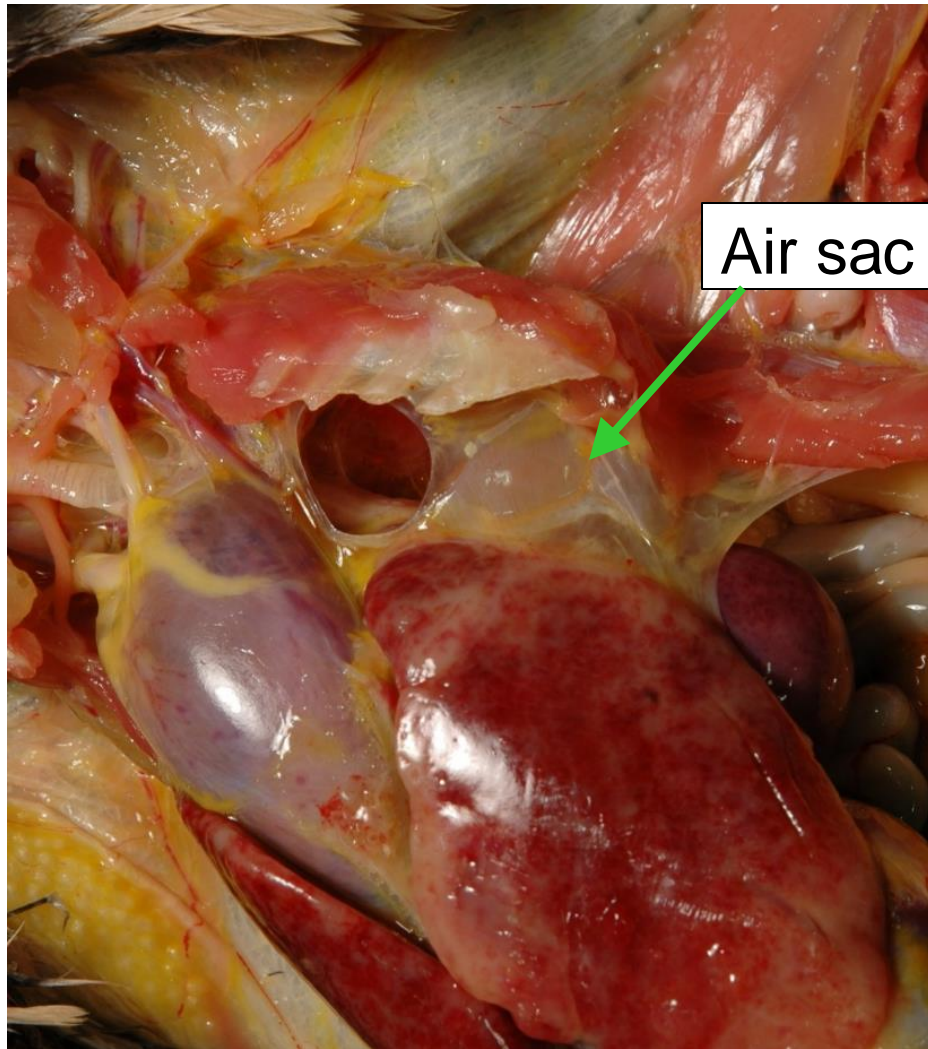


Remove keel by cutting ribs, coracoid bones bilaterally



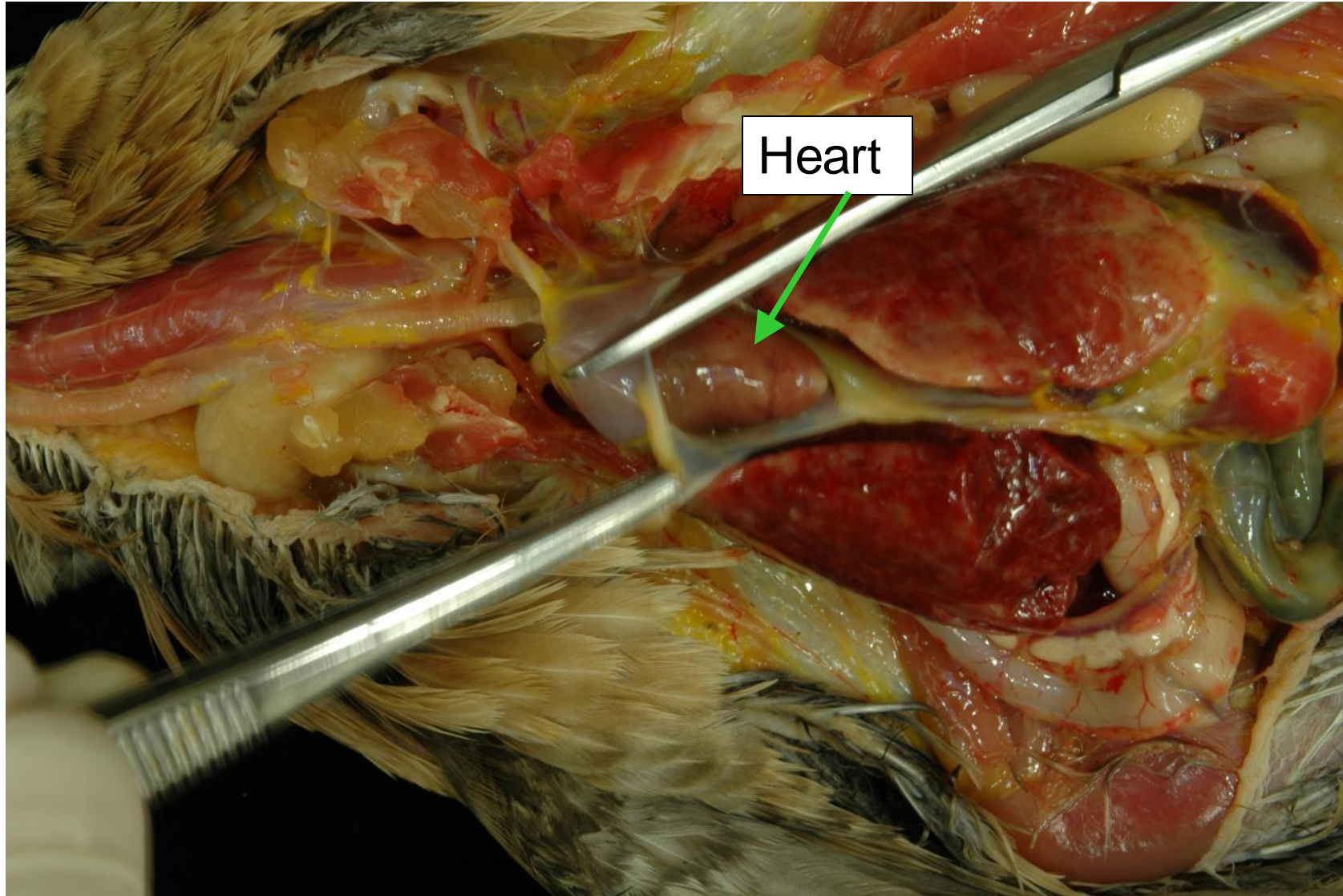
Note: handle tissues carefully to minimize contamination of internal organs

Visually examine cranial, caudal thoracic, abdominal air sacs, collect if abnormal



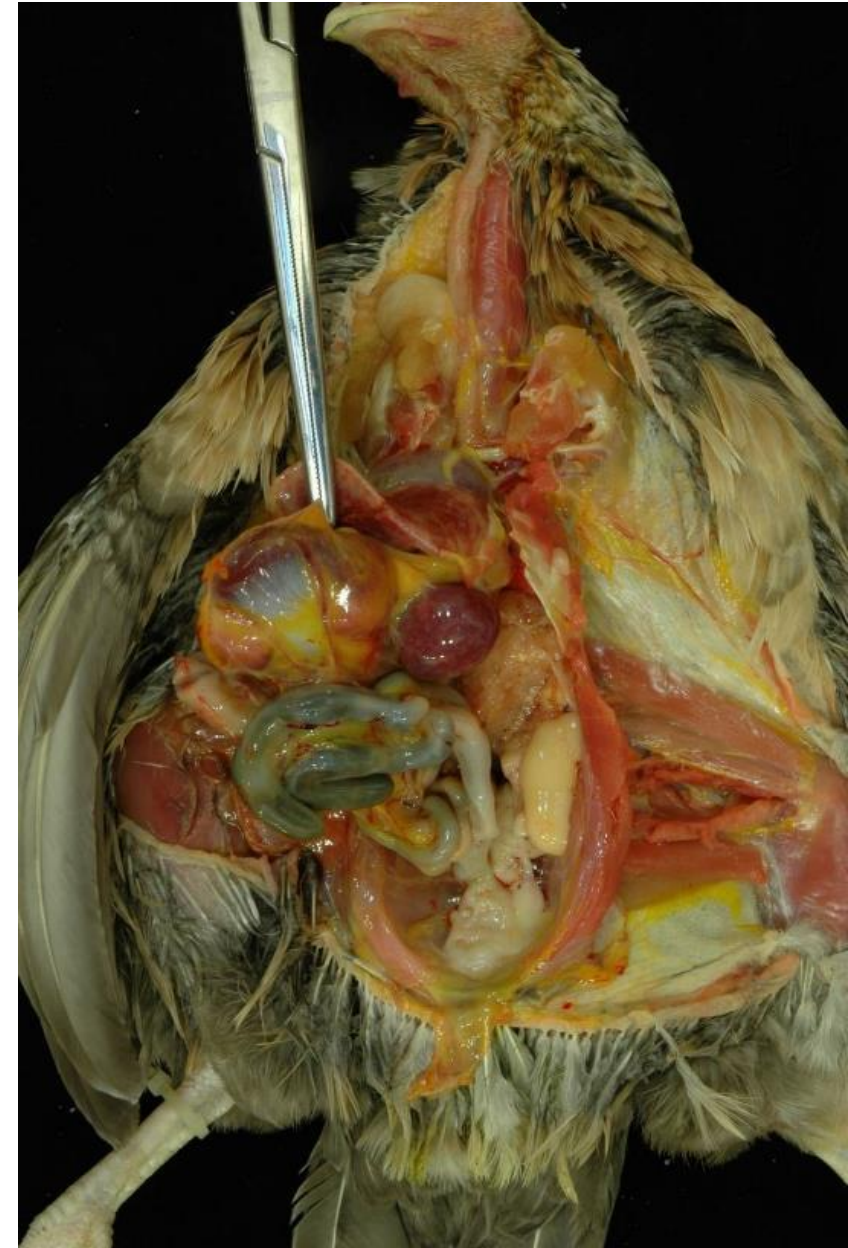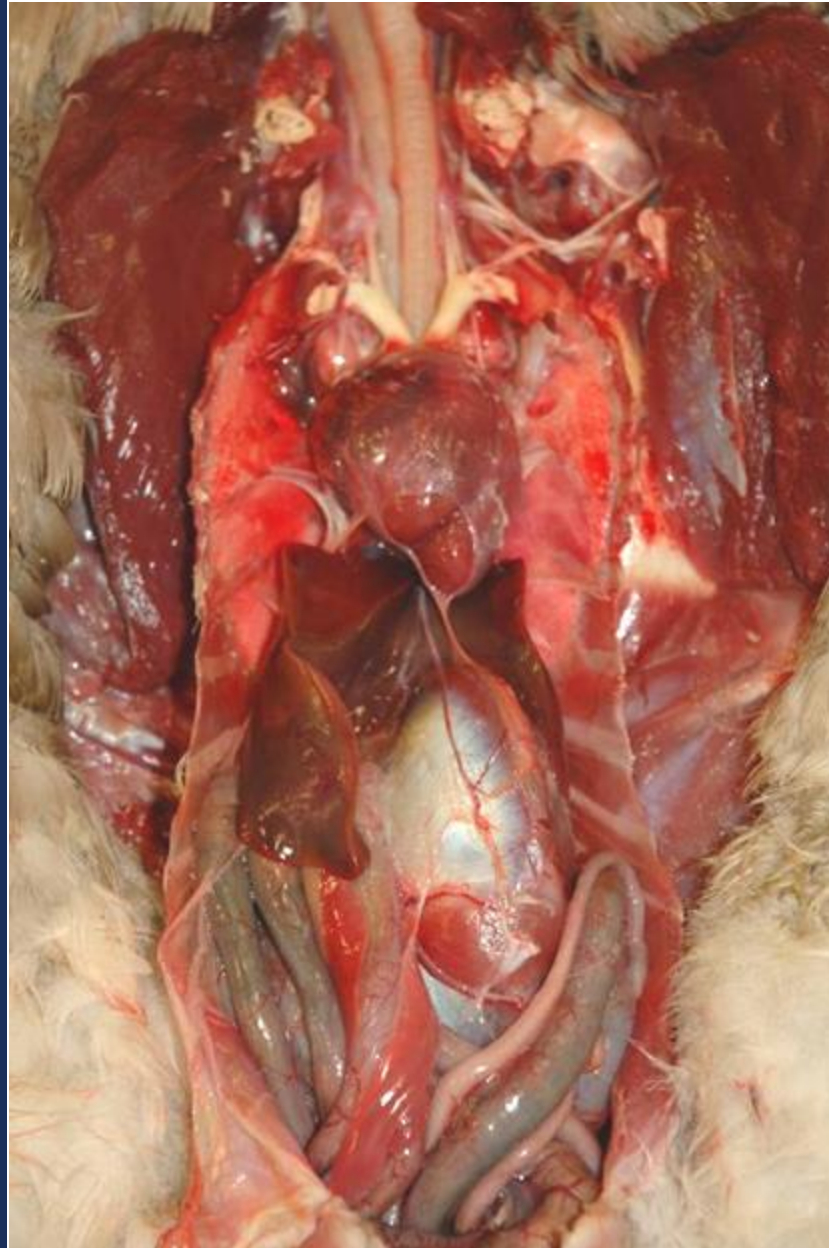<http://www.vetmed.ucdavis.edu/whc/pdfs/necropsy.pdf>

Open pericardial sac, collect abnormal fluid
Expose and externally examine the heart

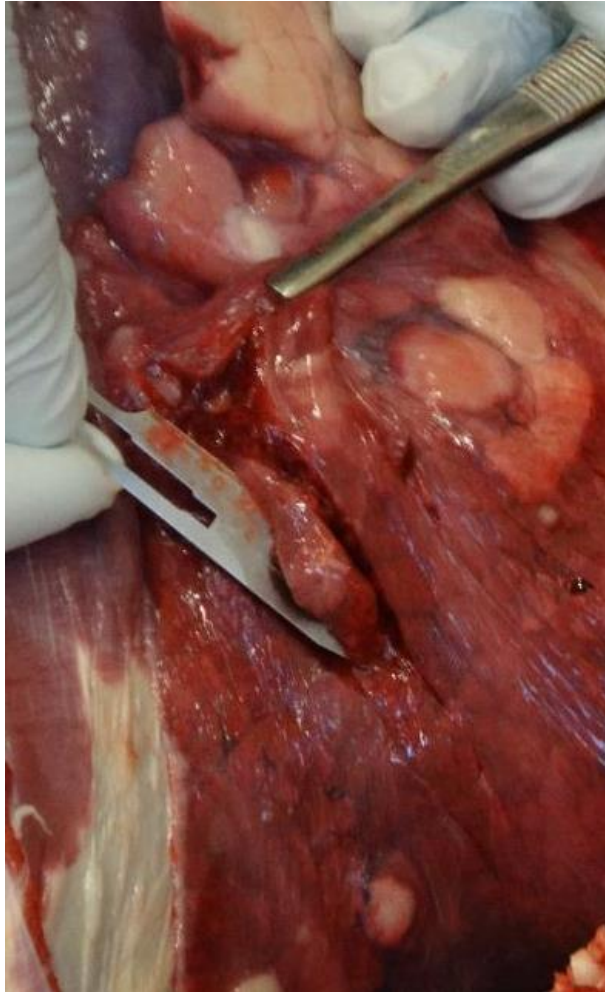

Visually examine coelomic viscera in situ

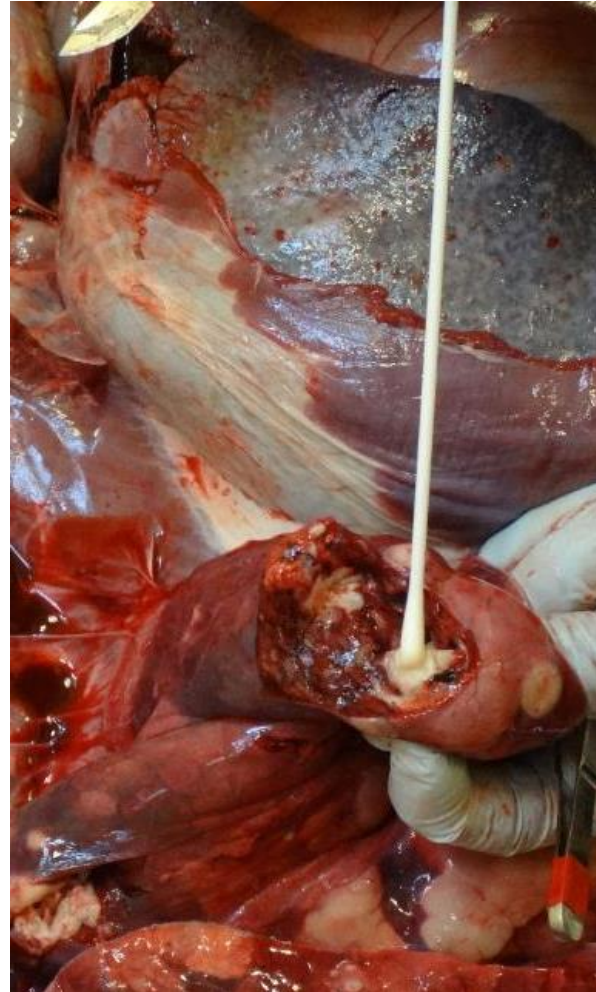Note: DO NOT touch or move
organs to prevent contamination
of tissues for sterile sampling
(see next slide)



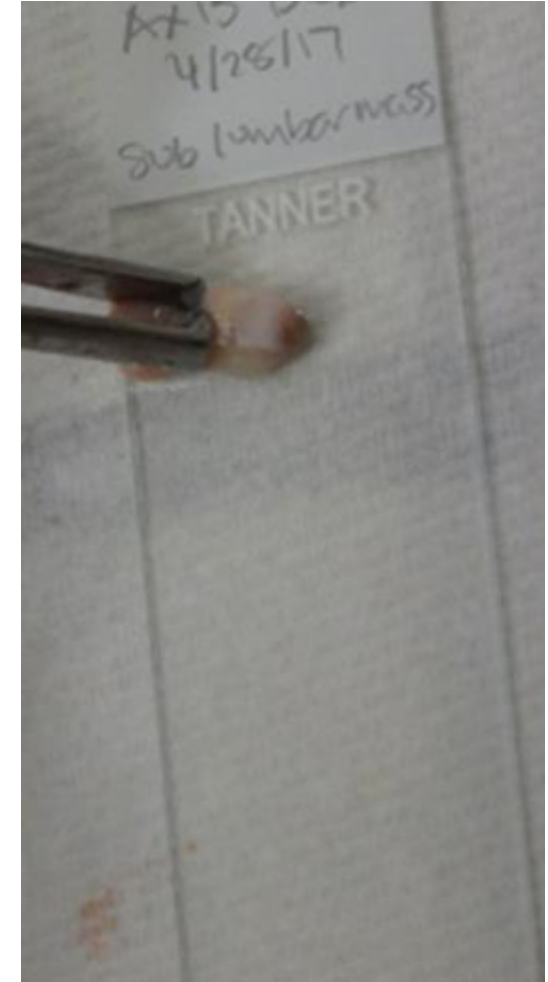
Collect sterile tissue samples for other diagnostics



Other tissues?

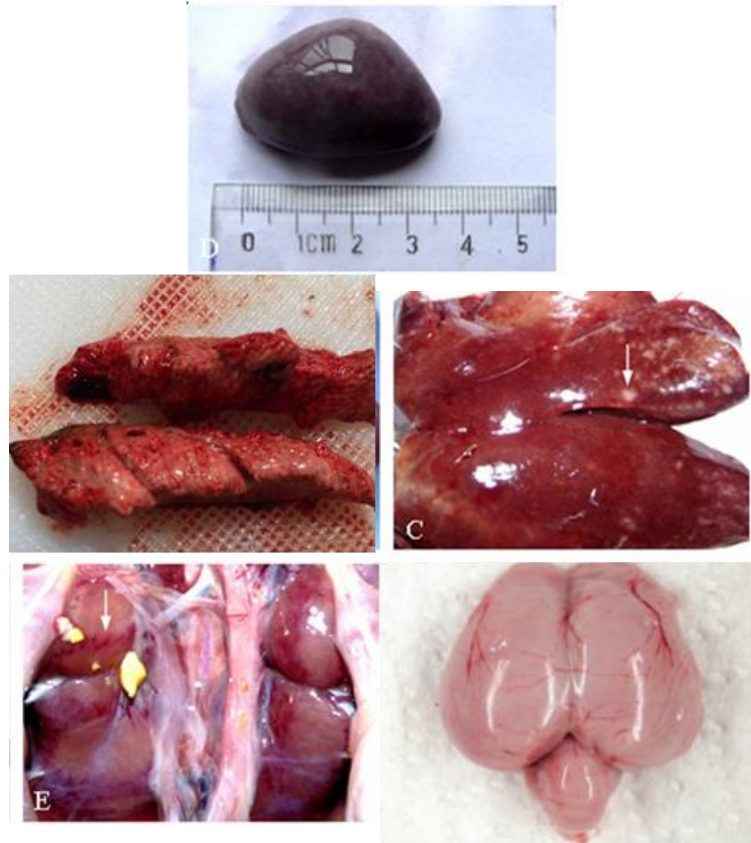

Microbiology?



Cytology?

Collect sterile tissue samples for other diagnostics



Molecular
diagnostics



Filter
paper

CHECKPOINT 2

Internal examination part 2


- **Body cavities**
- **Organs in situ**
- **Lesions**
- **Samples**



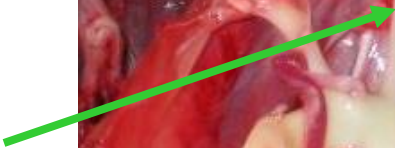Examine thyroid glands

Collect both glands


Thyroid gland



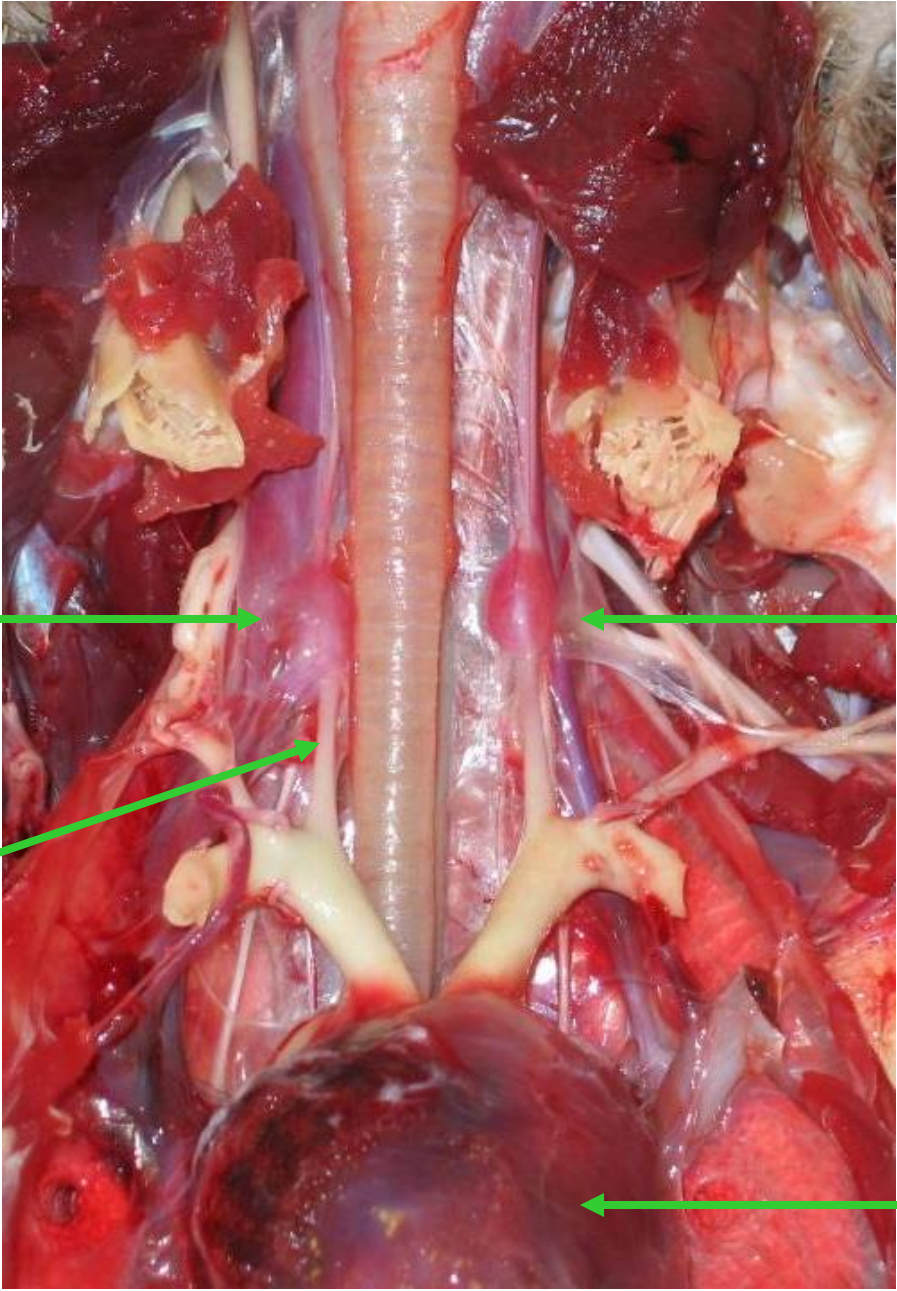

Carotid artery



Thyroid gland

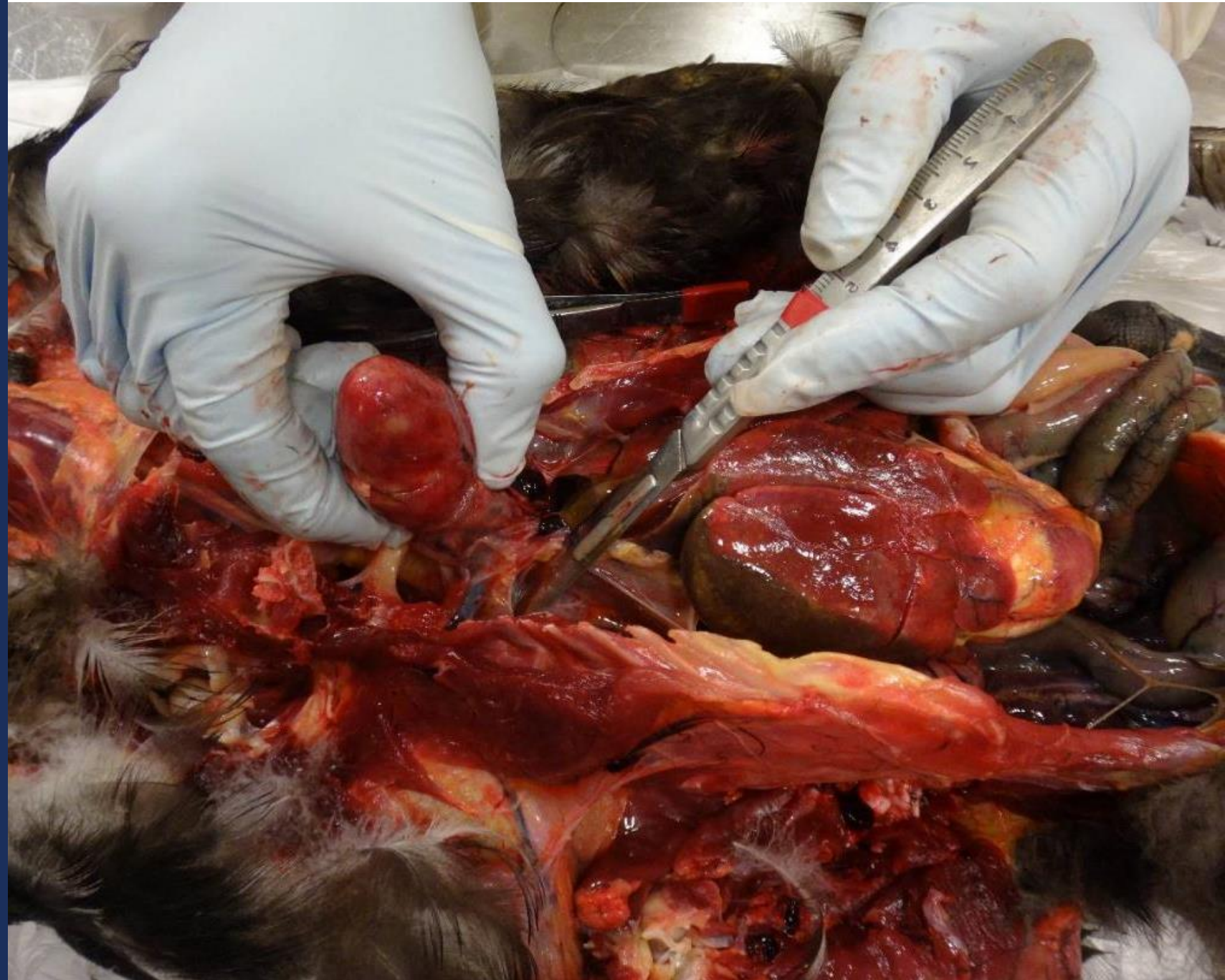

Heart



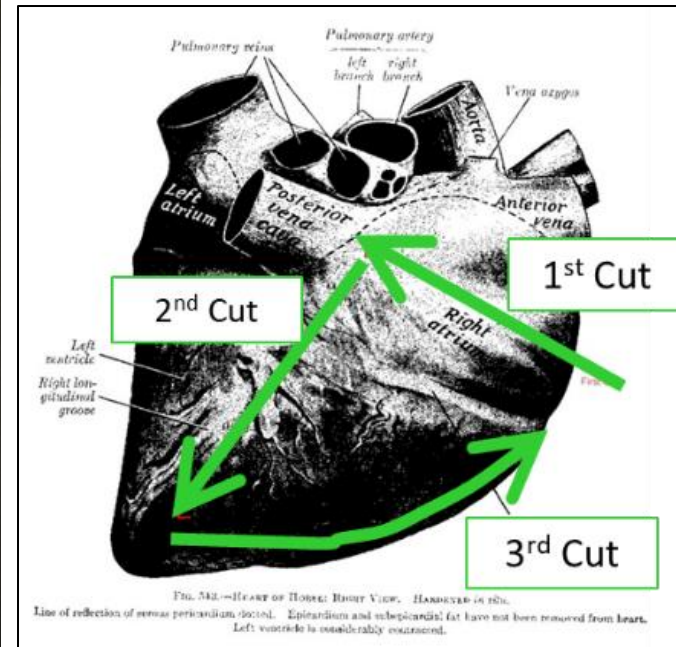
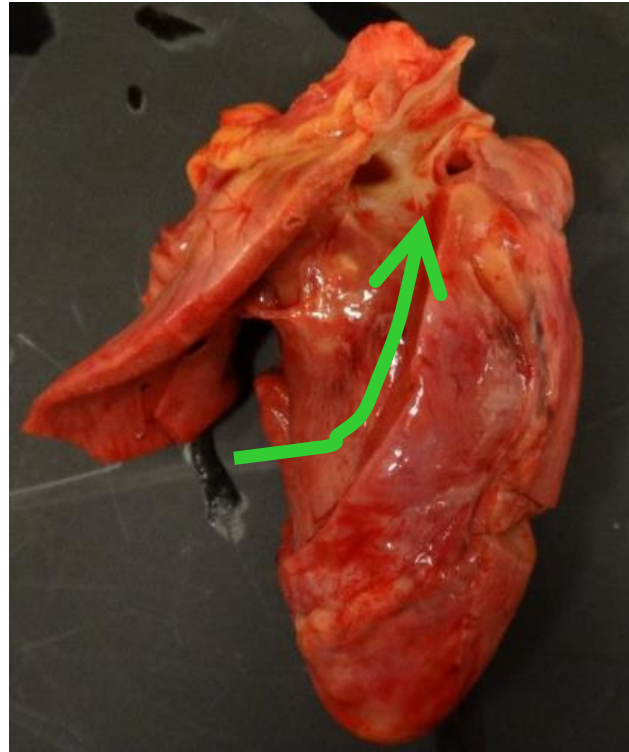
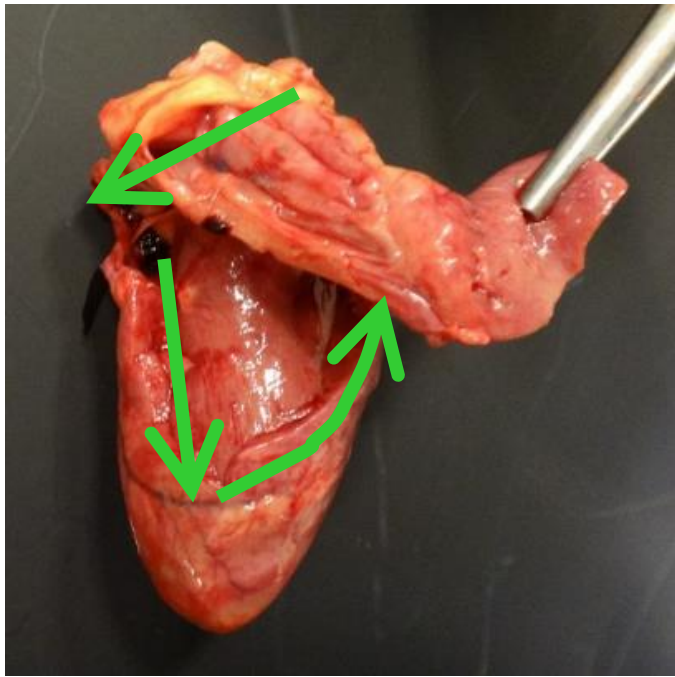
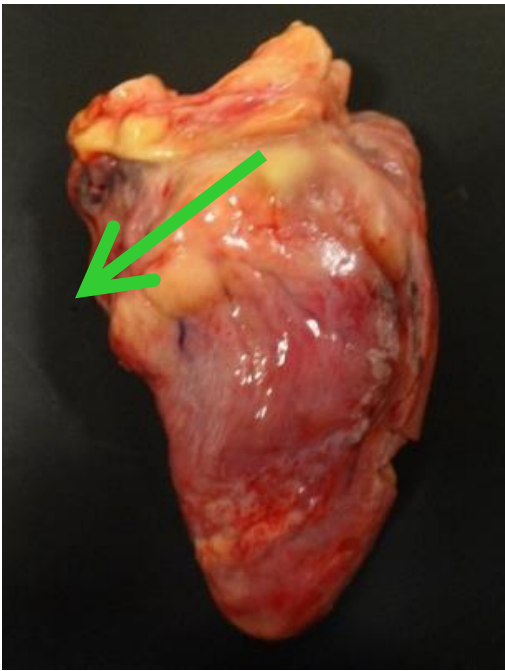
Remove, examine heart

Note: small hearts < 1.5 cm can
be placed whole in formalin



Examine and open right side of heart

- right atrium, right atrioventricular valve, right ventricle, pulmonic valve



Examine and open left side of heart

- left atrium, left atrioventricular valve, left ventricle, aortic valve

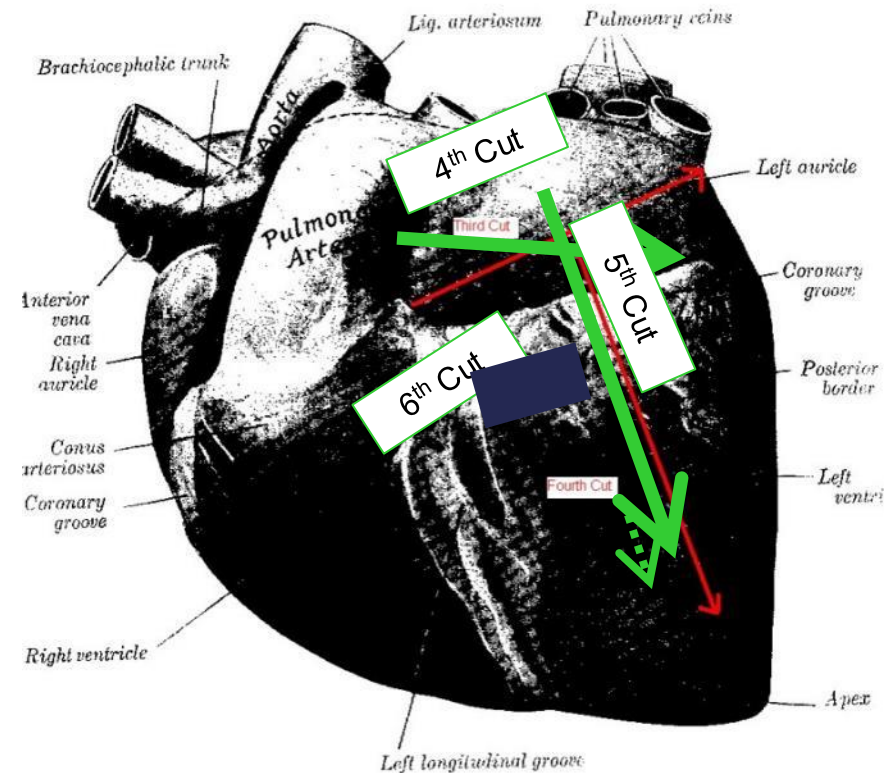
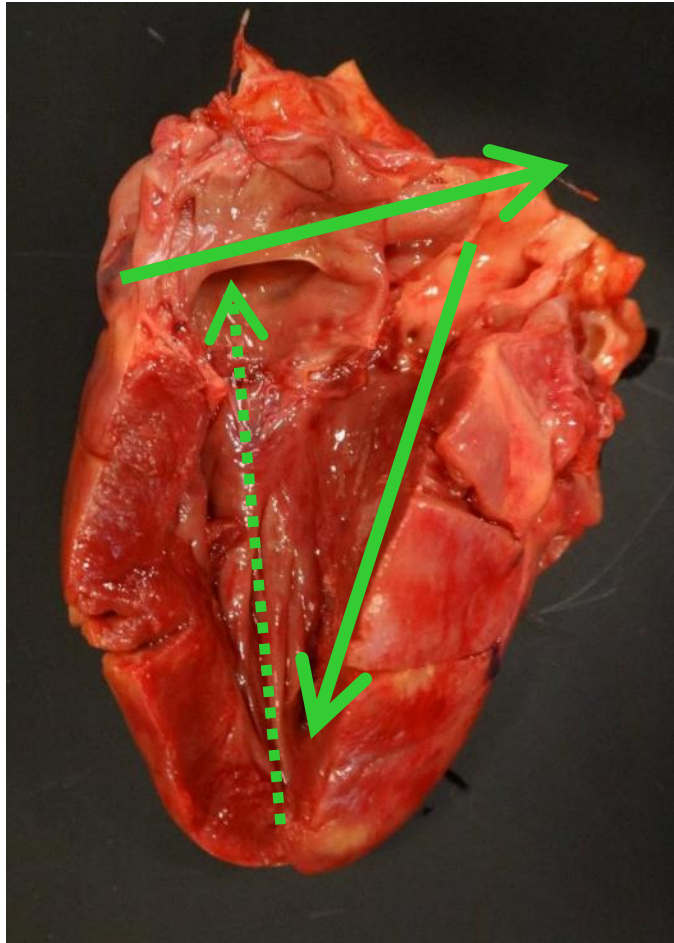
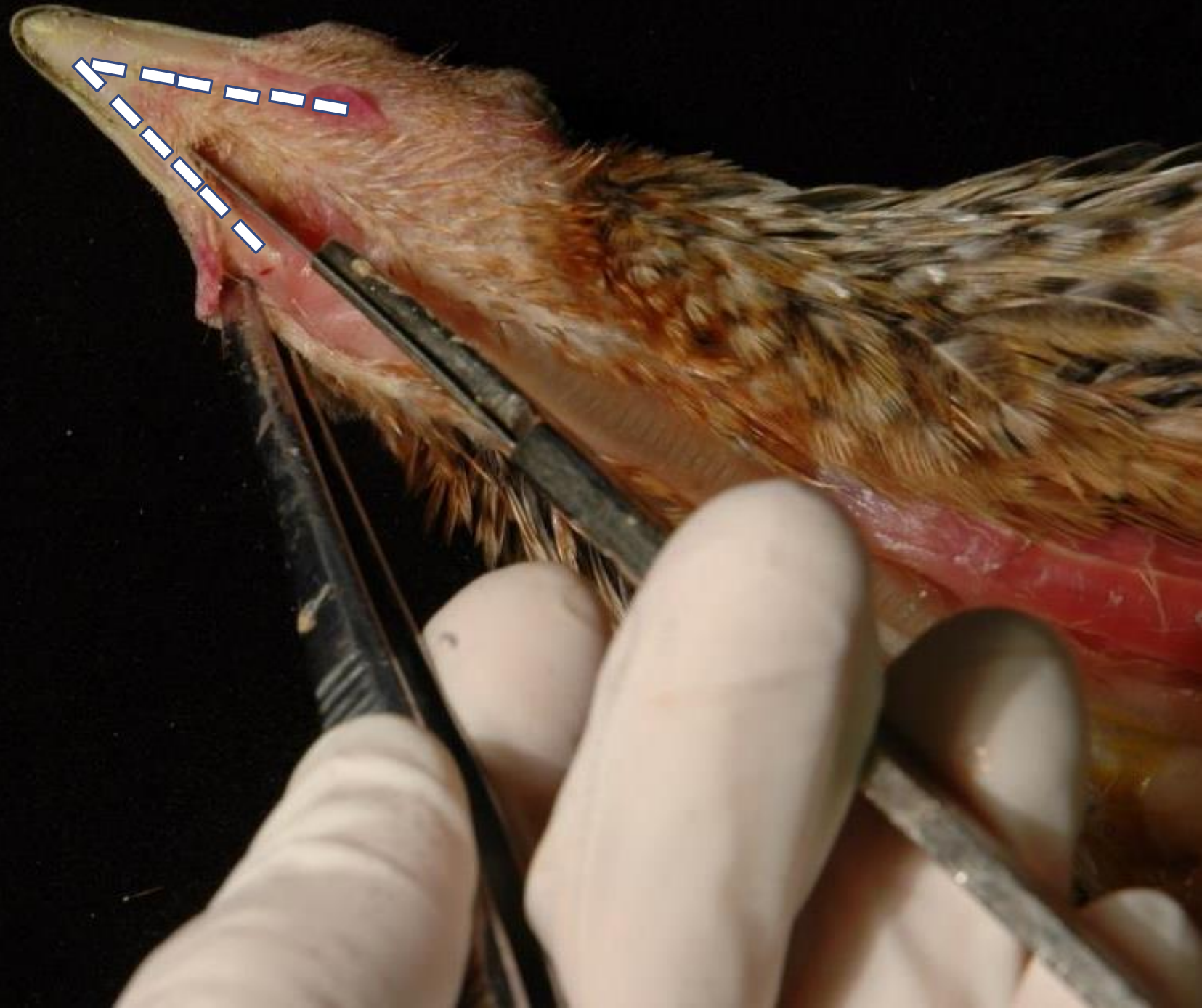

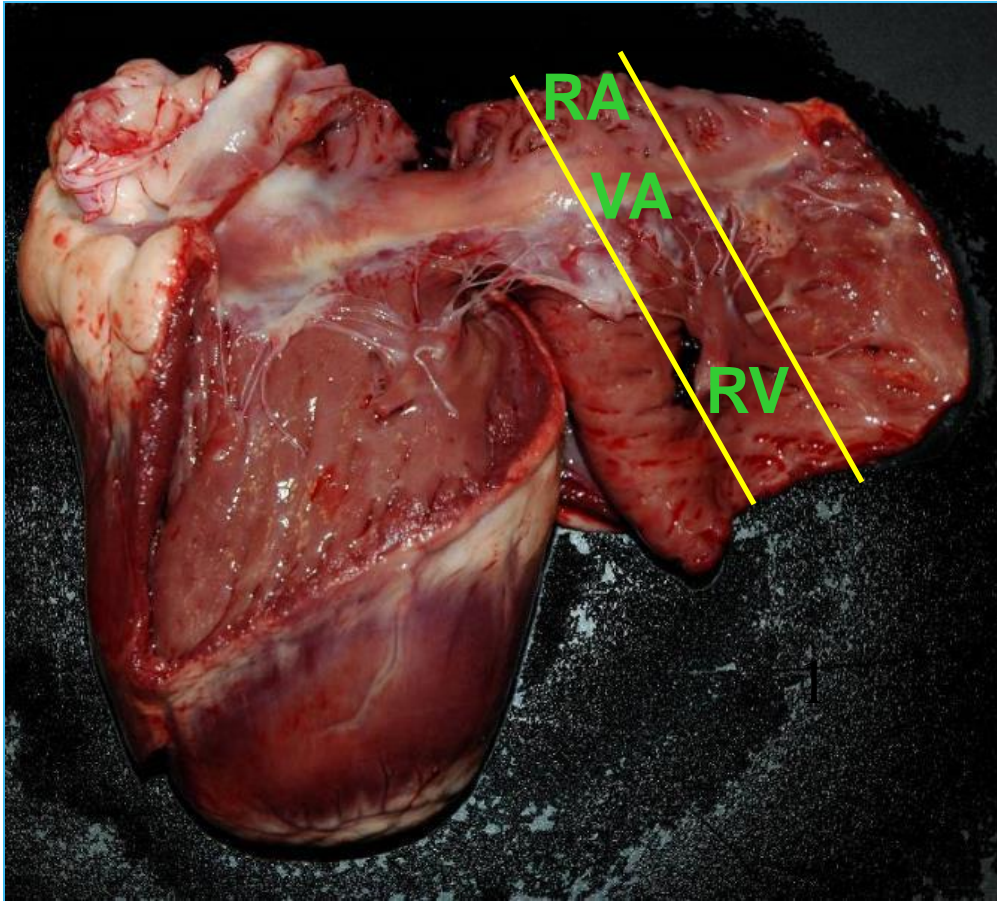
FIG. 512.—HEART OF HORSE; LEFT VIEW. HARDENED *in situ*. The dotted line indicates the line of reflection of the serous pericardium. The epicardium and subepicardial fat have not been removed.

Remove upper
respiratory &
gastrointestinal
tracts together

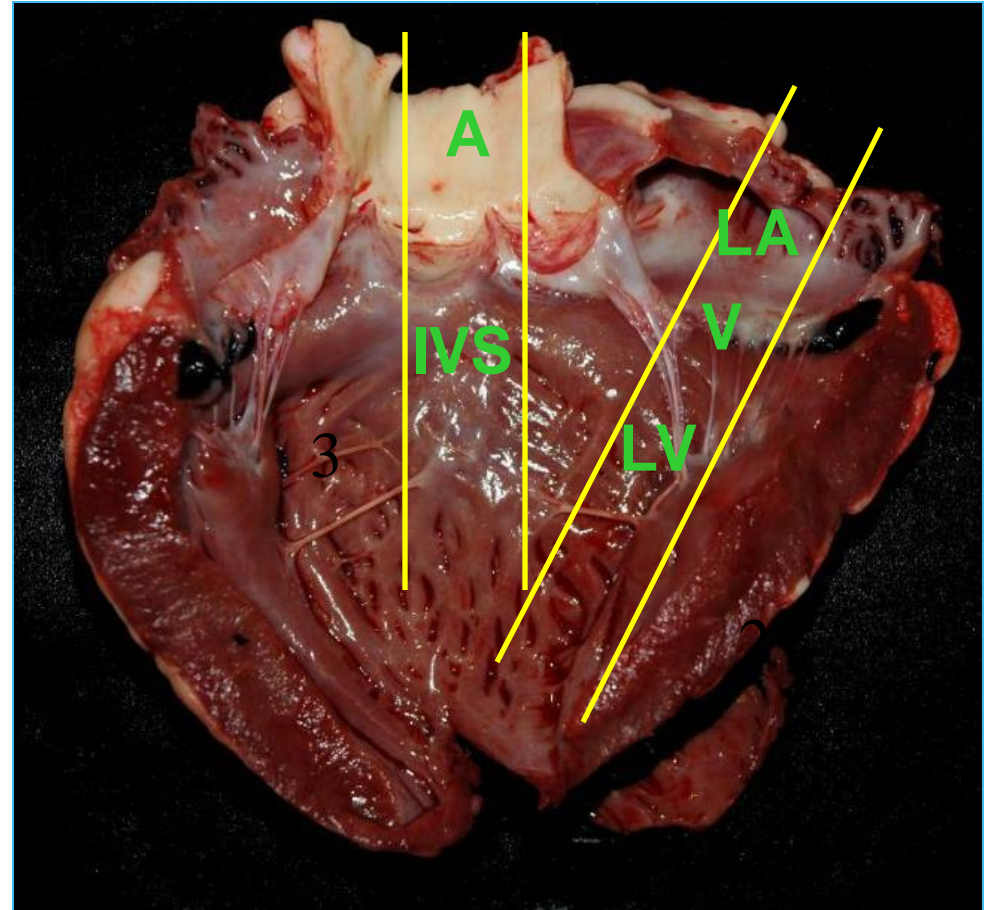
Cut skin of ventral
mandible, bilaterally



Collect 3 samples of heart

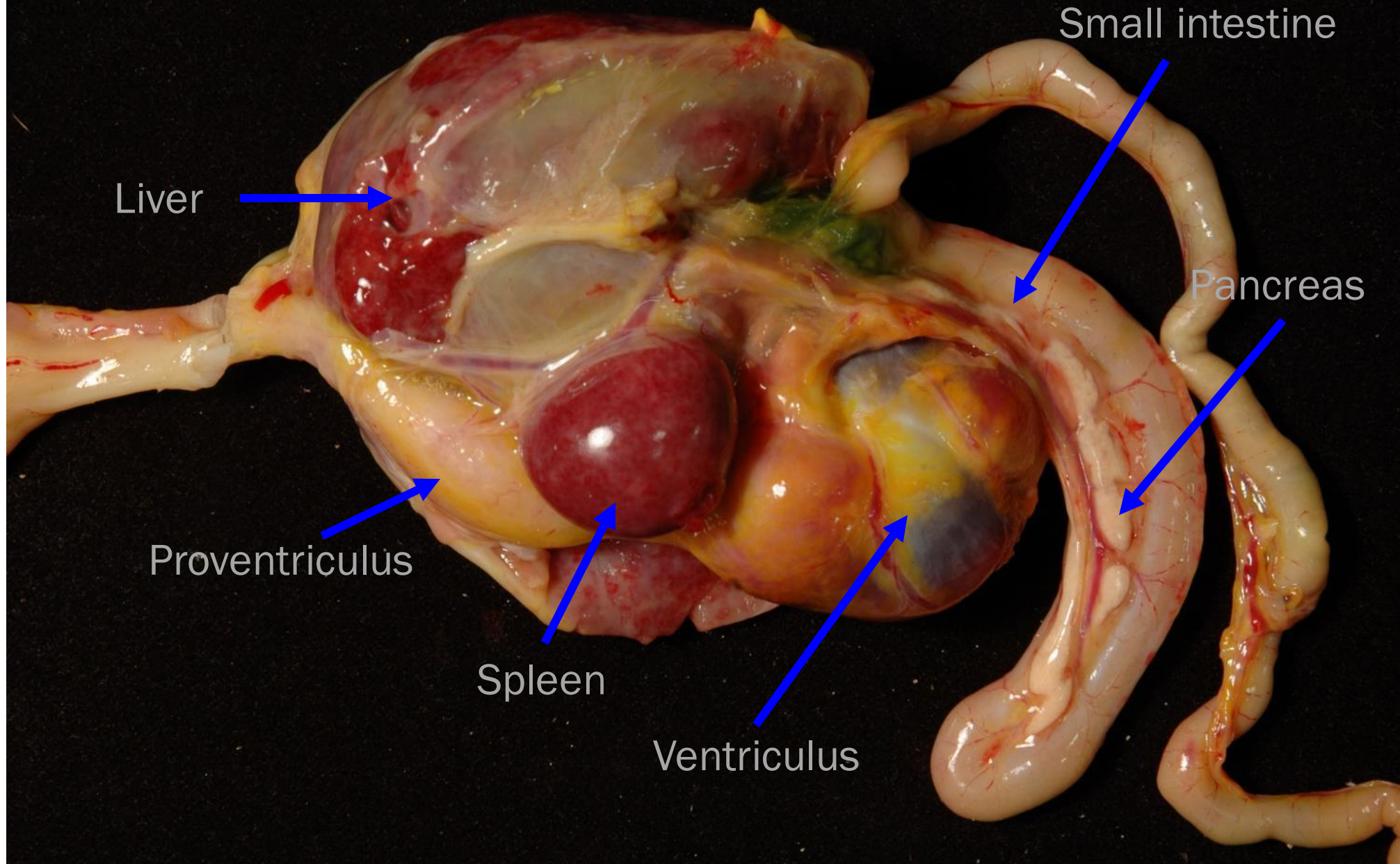


1. Right atrium (RA), ventricle (RV), valve (VA)

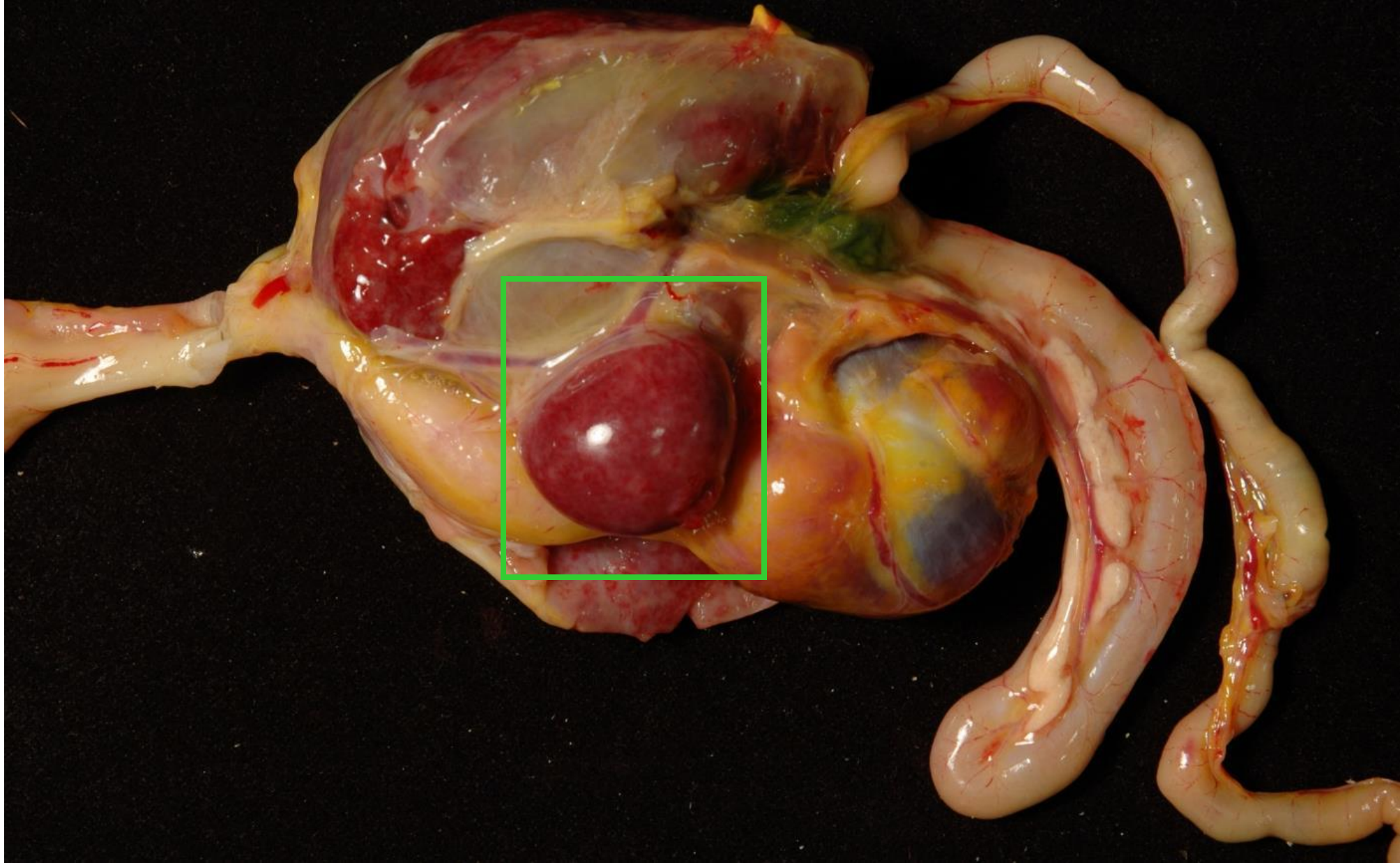


2. Left atrium (LA), ventricle (LV), valve (V)
3. Interventricular septum (IVS), aorta (A)

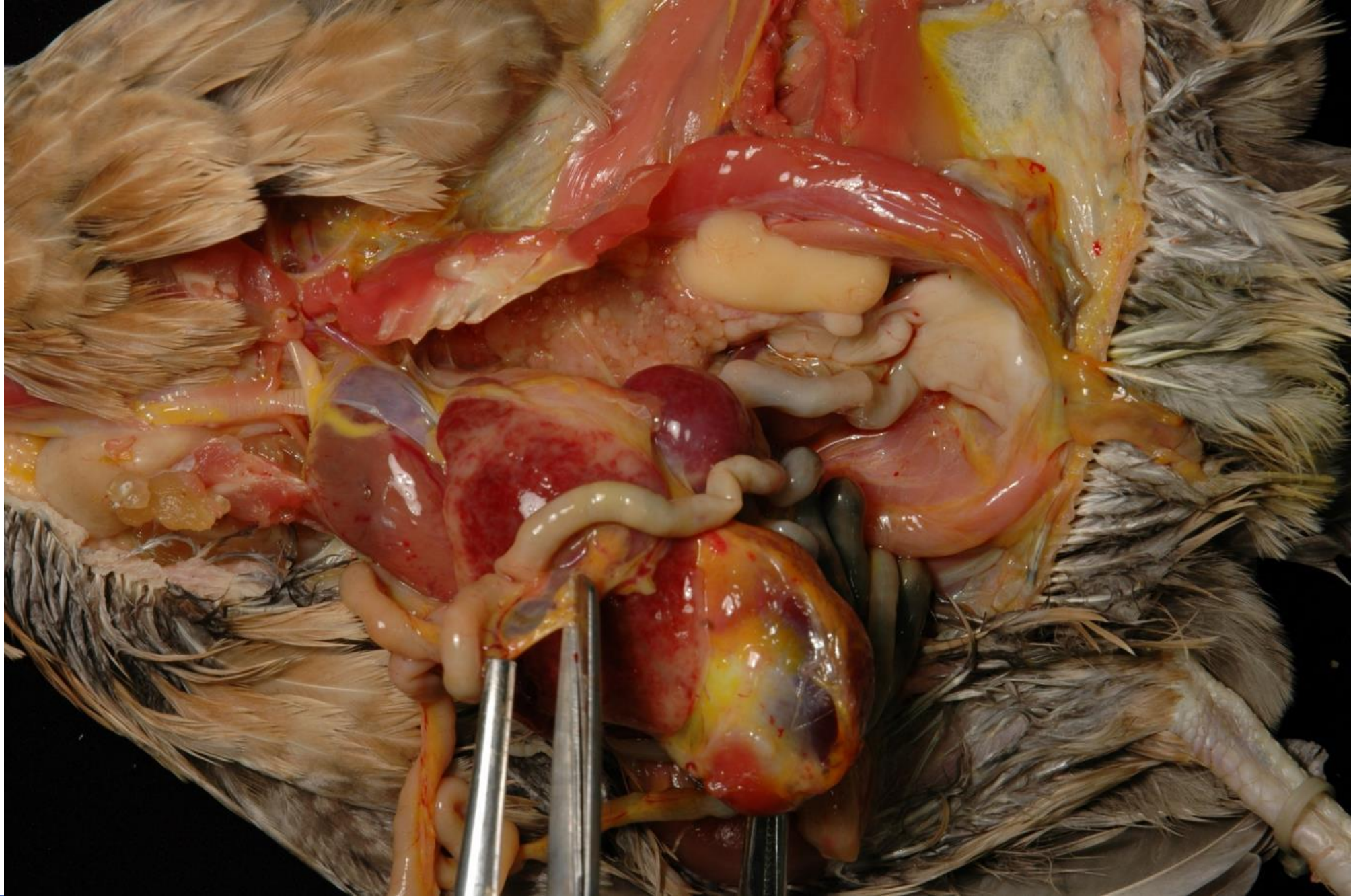Coelomic viscera



Examine,
remove,
and collect
spleen

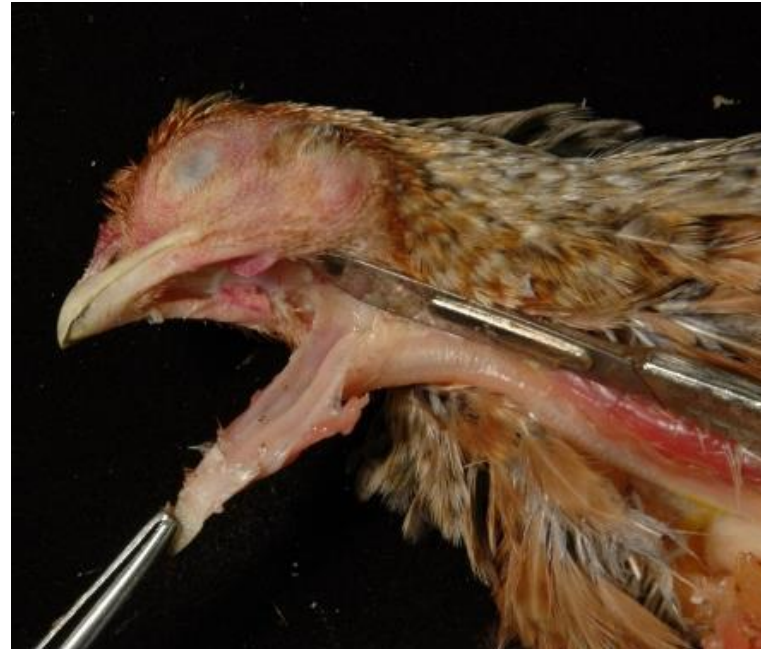
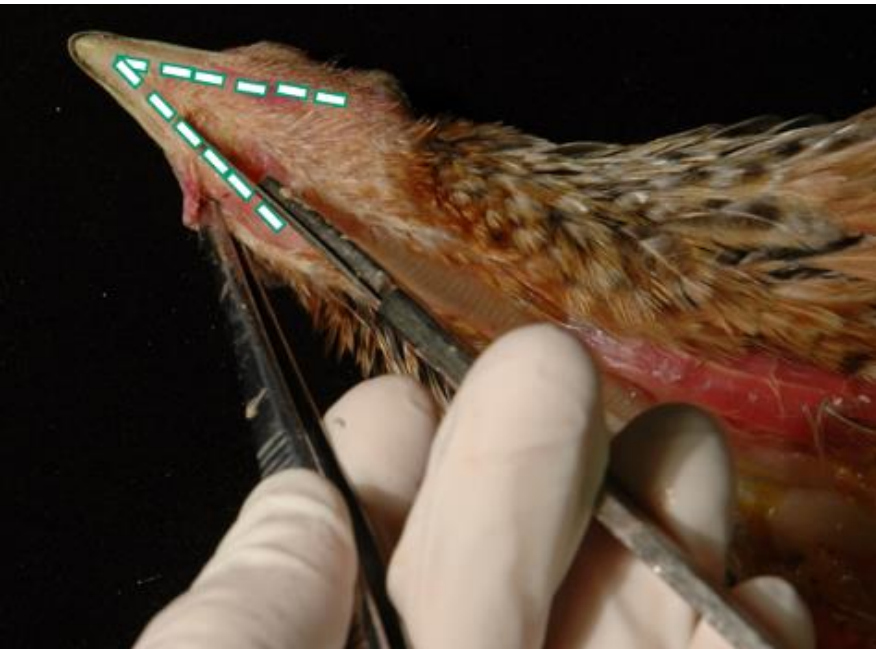
Linearize intestinal tract

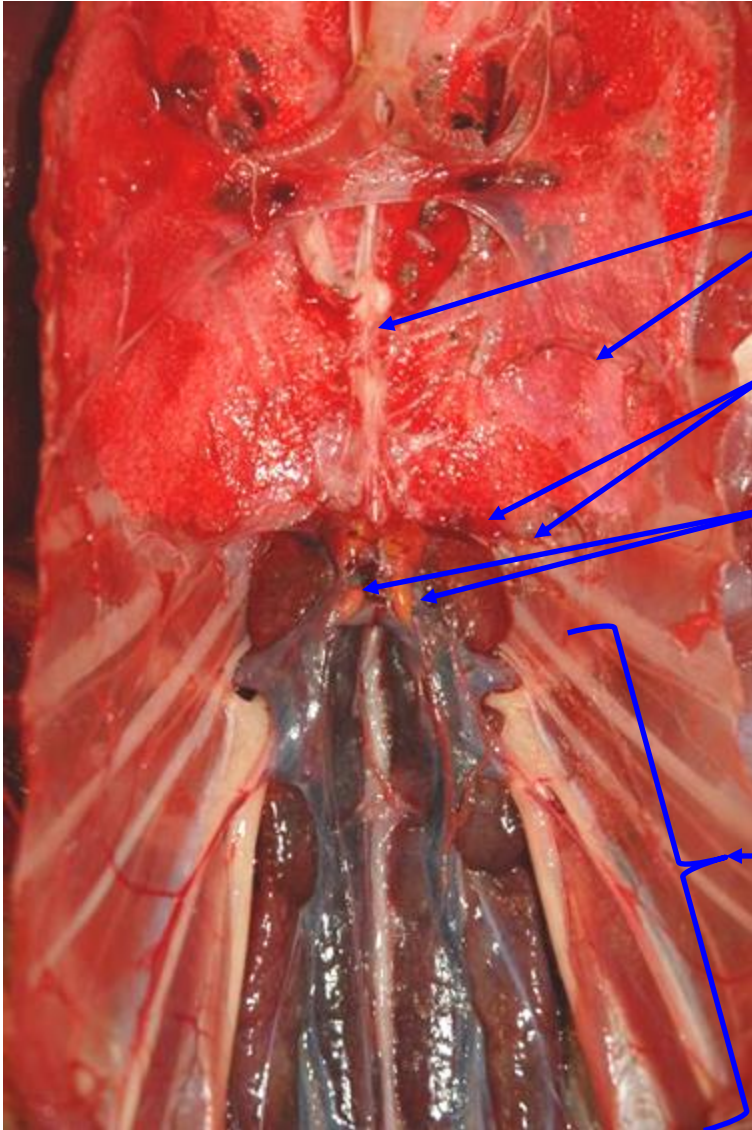


Remove upper respiratory & gastrointestinal tracts together

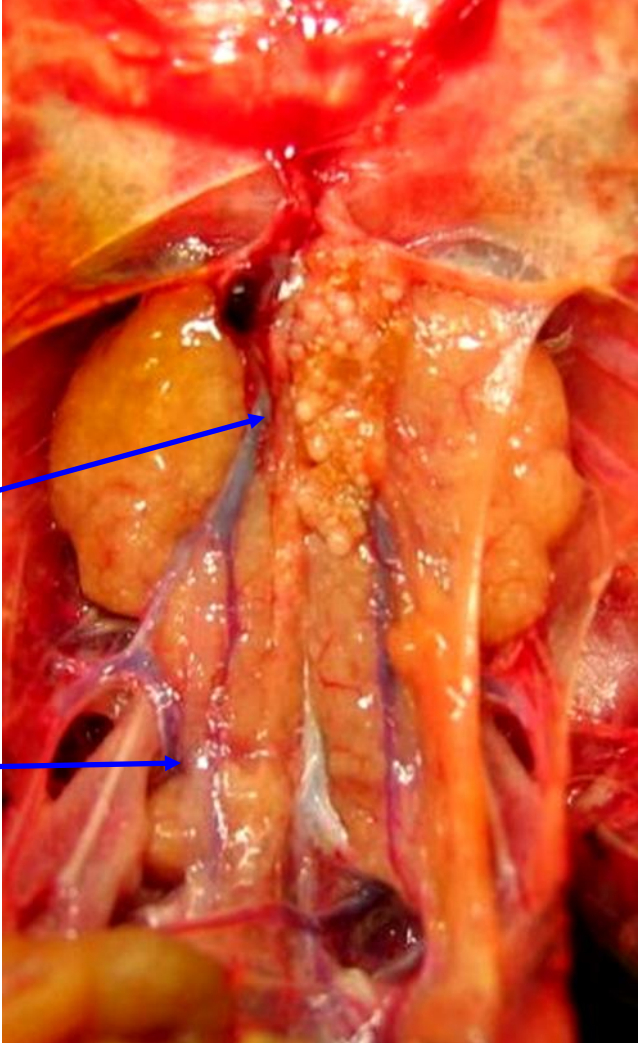
- Cut skin of ventral mandible, bilaterally
- Reflect tongue, transect hyoid
- Remove tongue, trachea, esophagus, gastrointestinal tract, including already cut sections (tongue to vent)
- Set aside




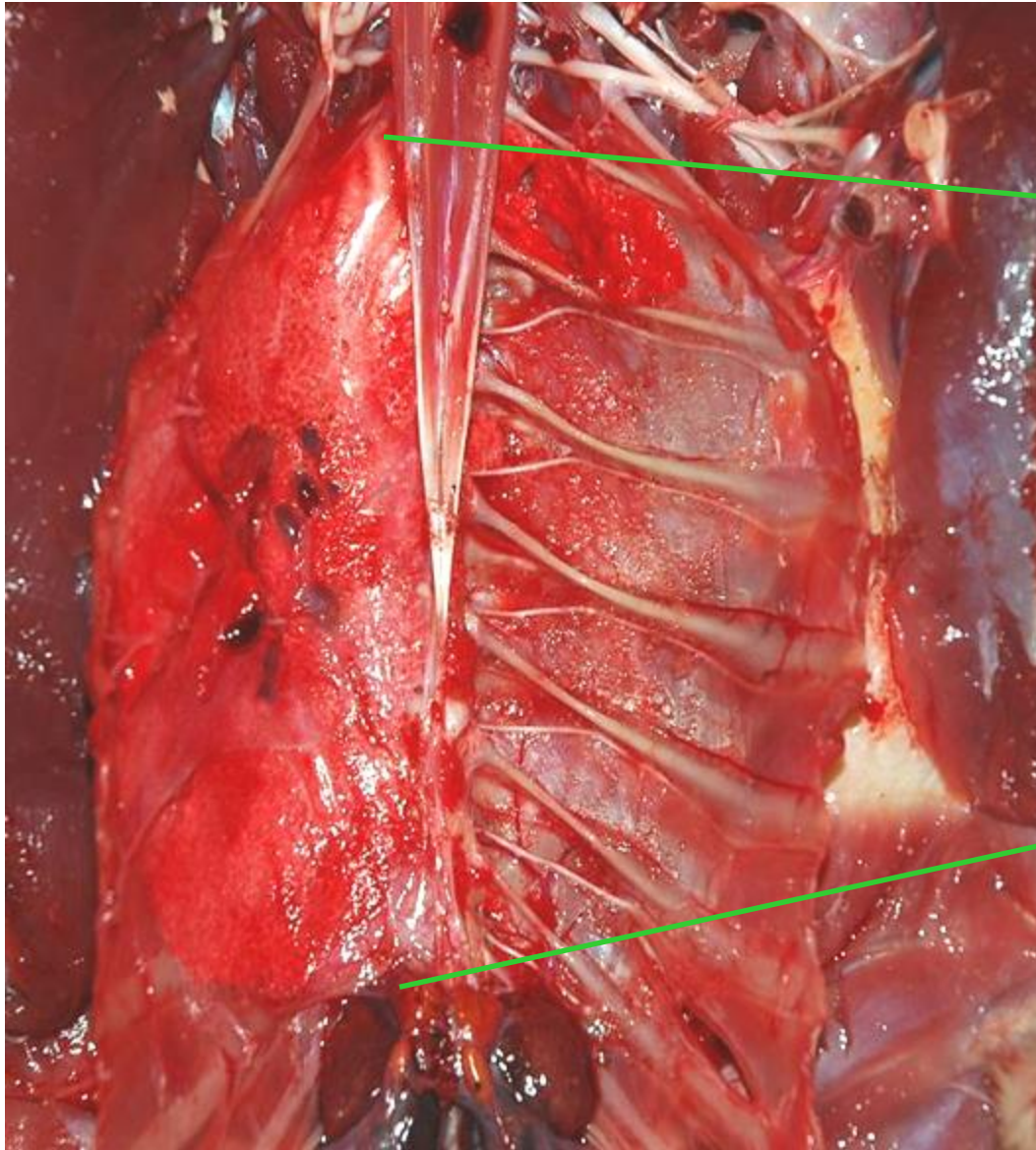
Examine remaining organs in situ



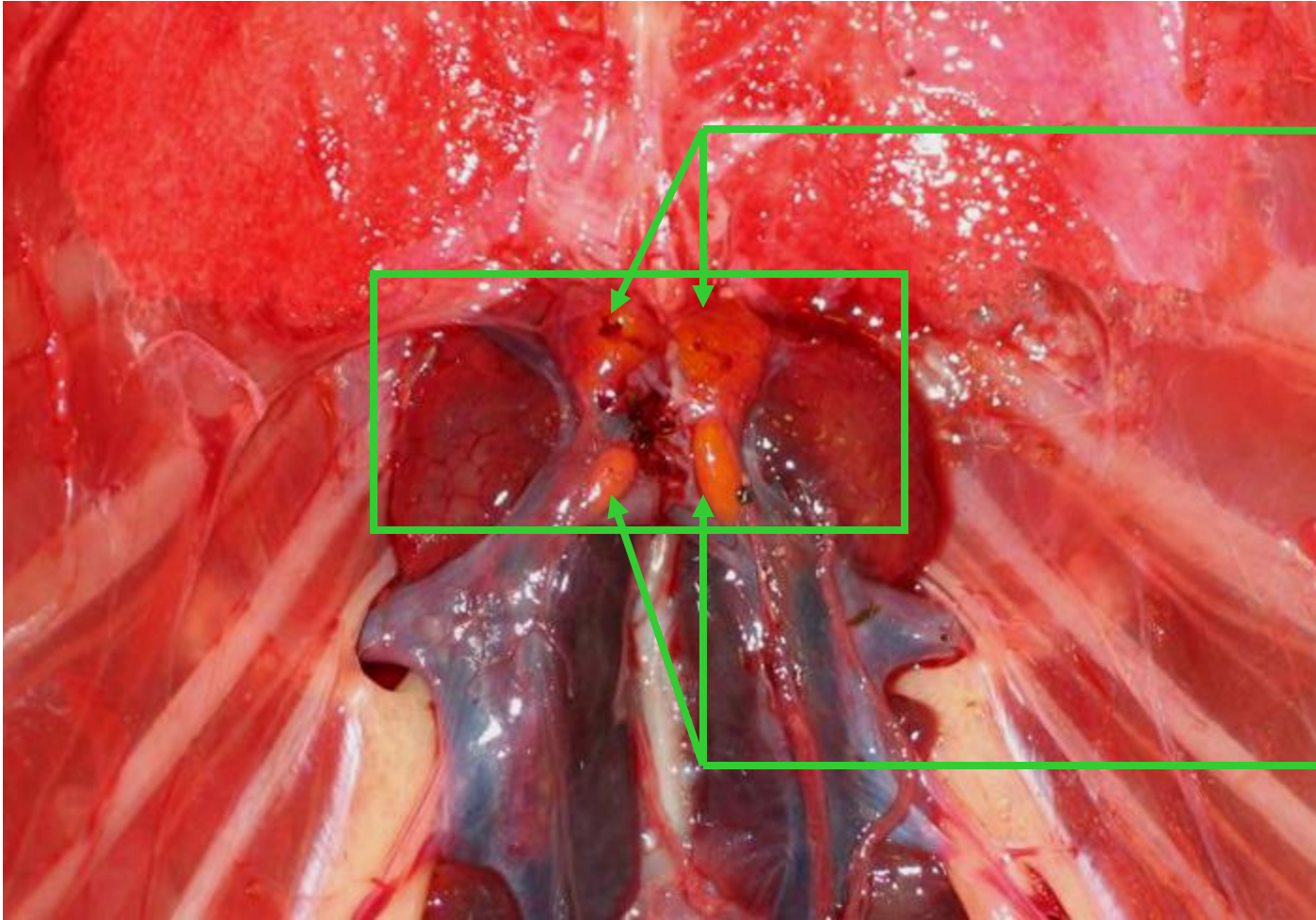
Lung
Adrenal glands
Testes
Ovary
Kidneys



Remove, serially section, sample lung



Male: Examine, collect testes, adrenal glands with kidney

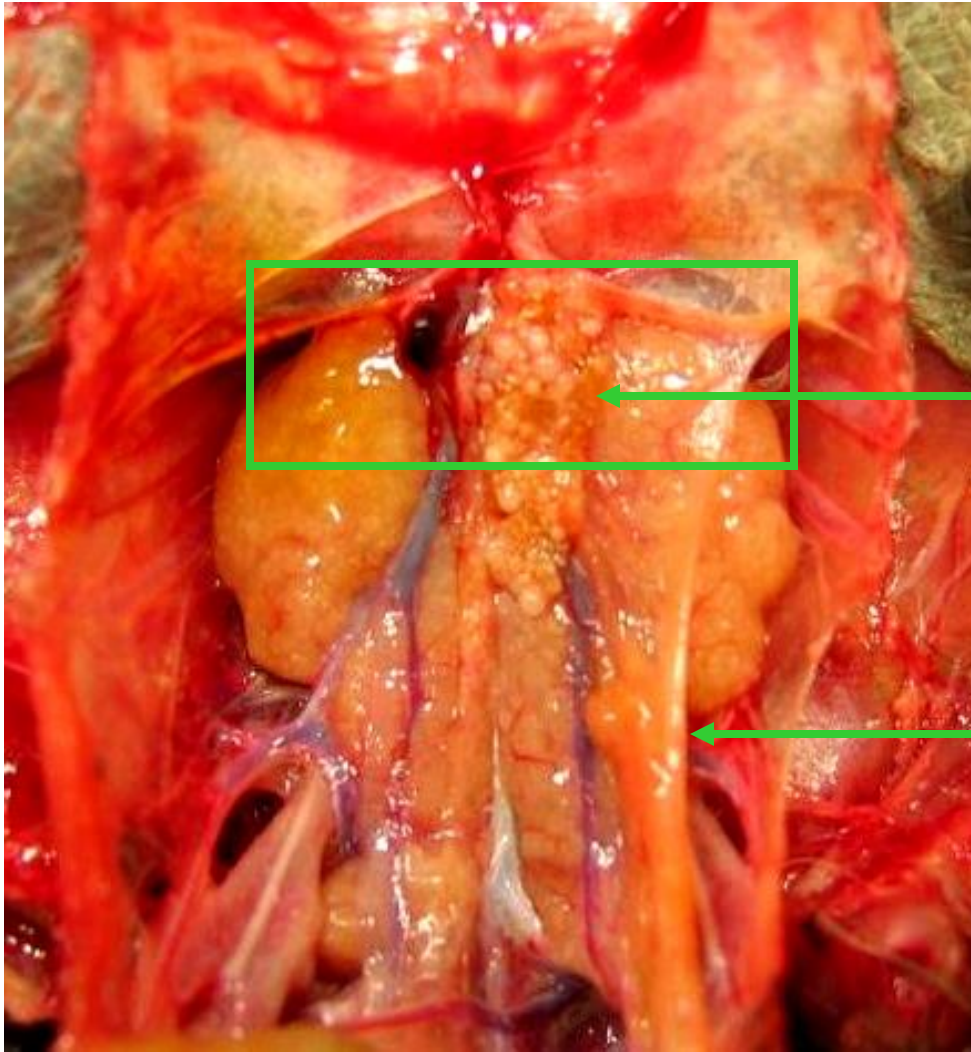


Adrenal glands

Testes

Note: collect testes, adrenal glands, kidney independent of each other in large birds

Female: Examine, collect ovary, adrenal glands, kidney, oviduct

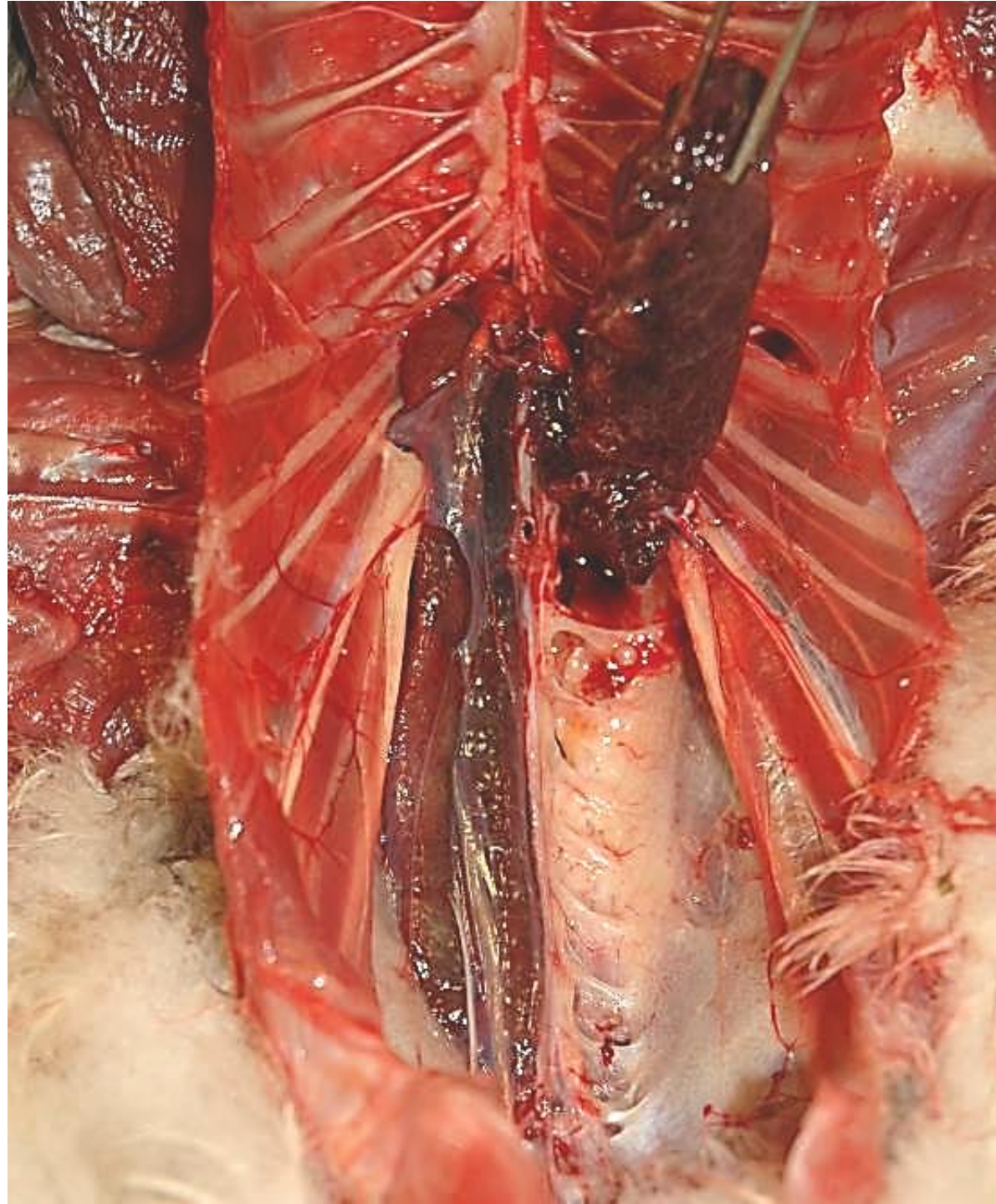

Ovary

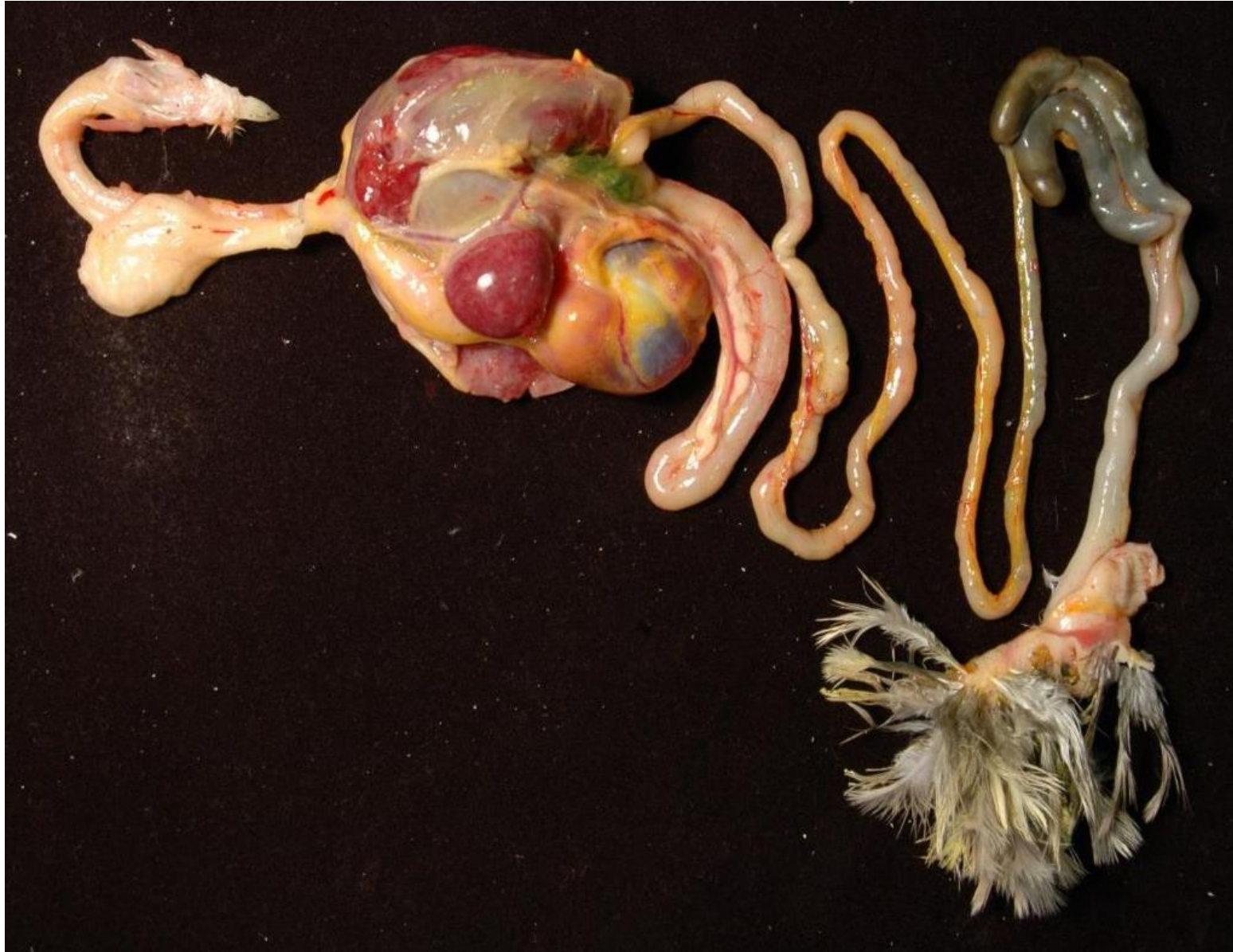Oviduct

Note: collect ovary, oviduct, adrenal glands, kidney independent of each other in large birds

Remove,
serially section,
sample kidneys



Examine upper respiratory and gastrointestinal systems

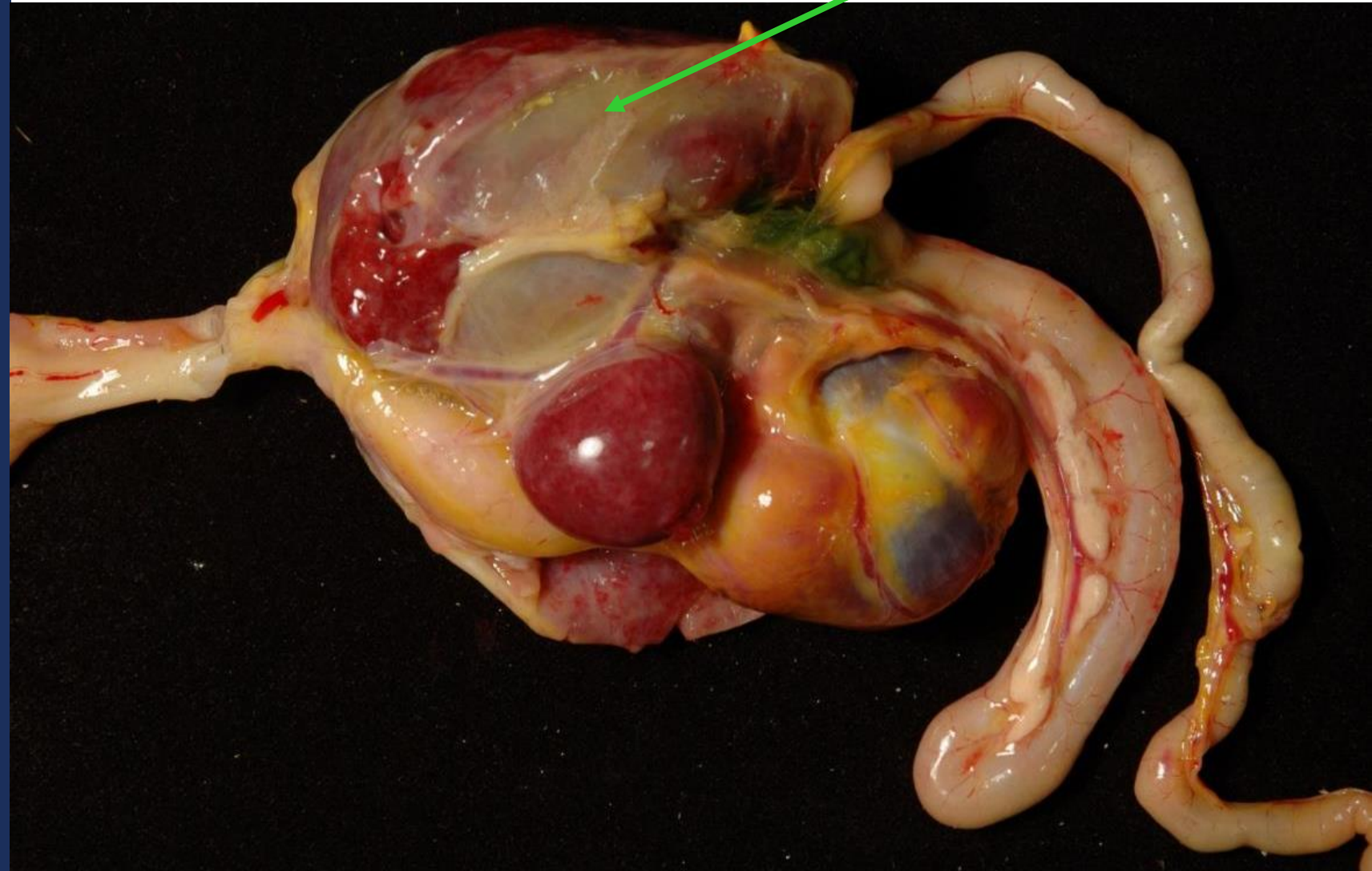


Check patency
of gall bladder

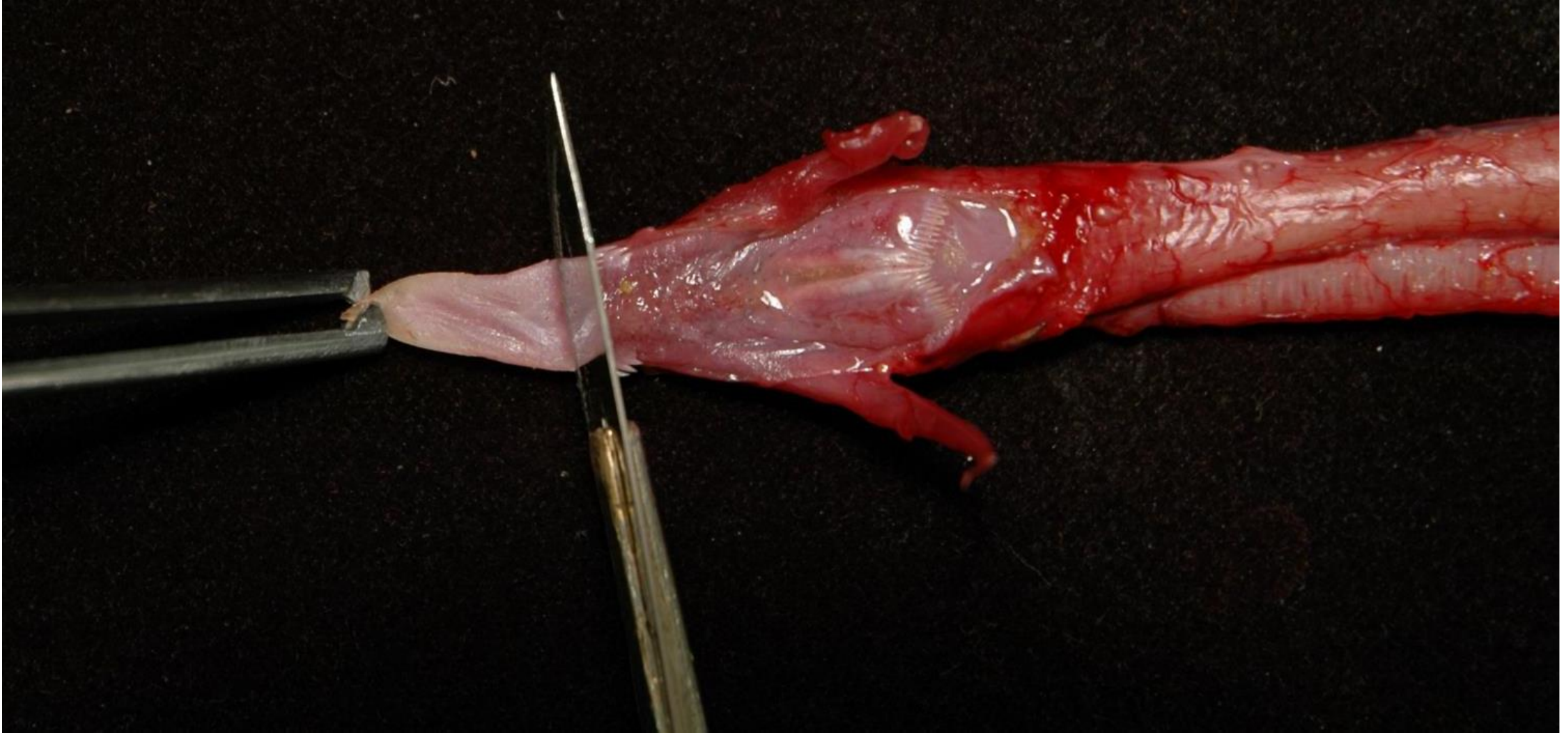
Remove liver,
serially section

Collect liver, gall
bladder

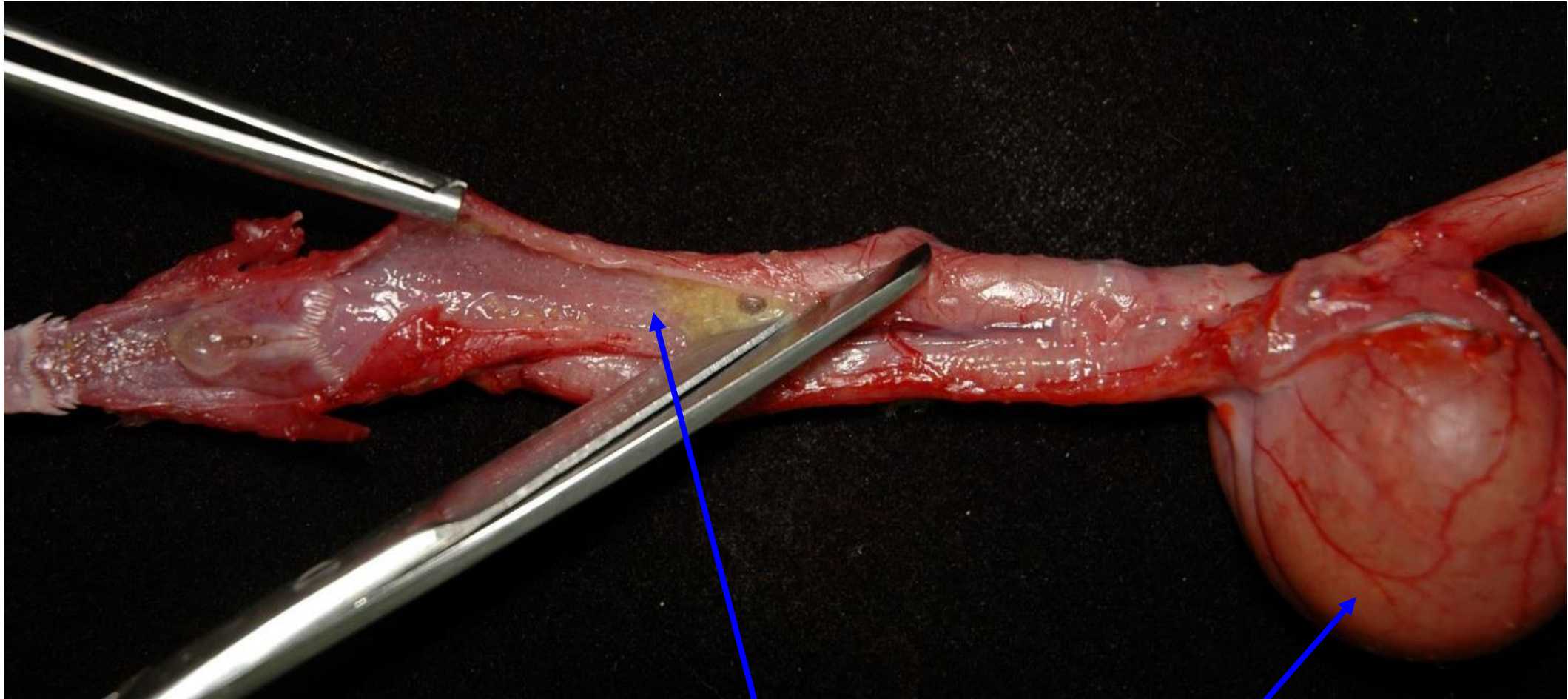
Liver



Examine tongue Collect sample



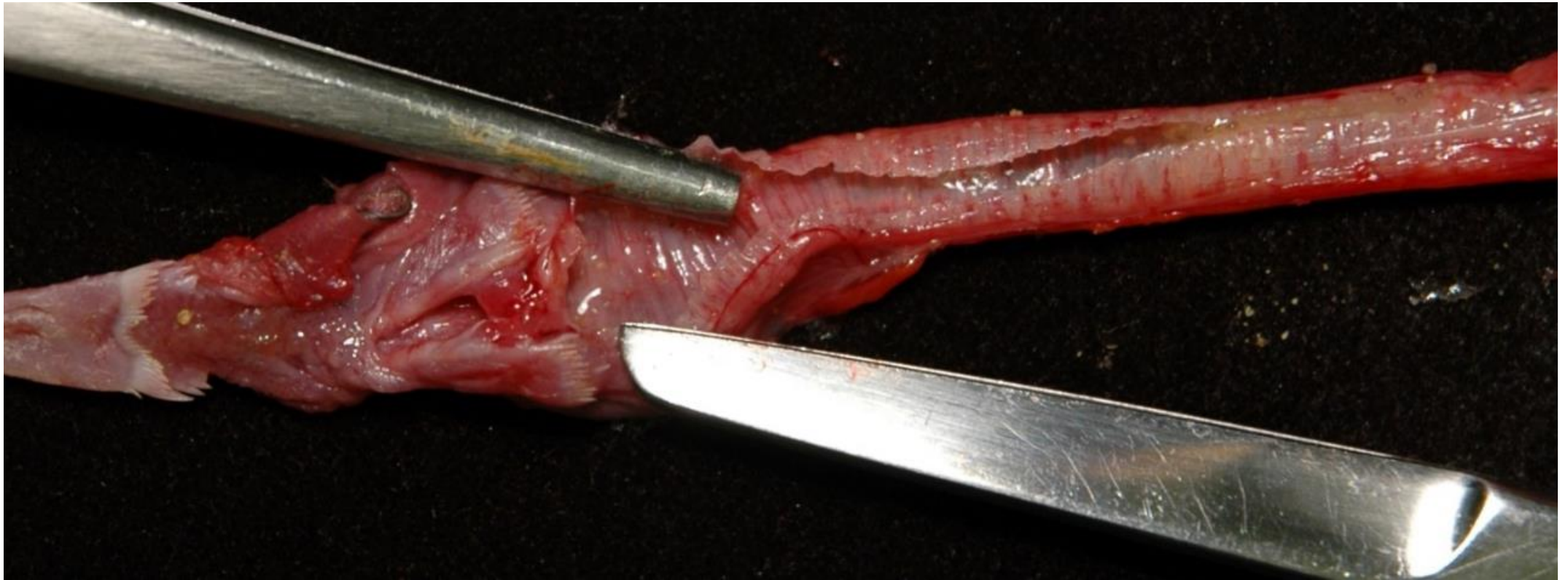
Open, examine esophagus, crop



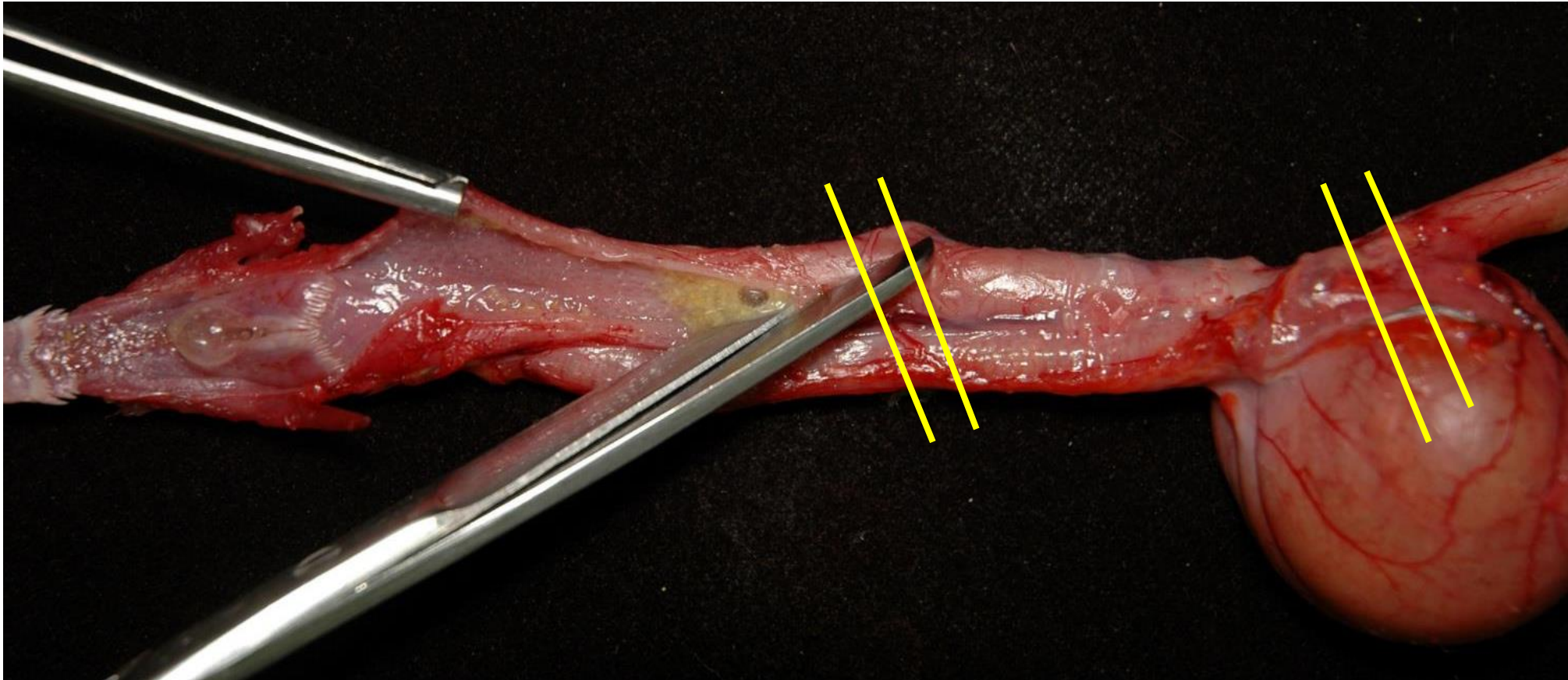
Esophagus

Crop

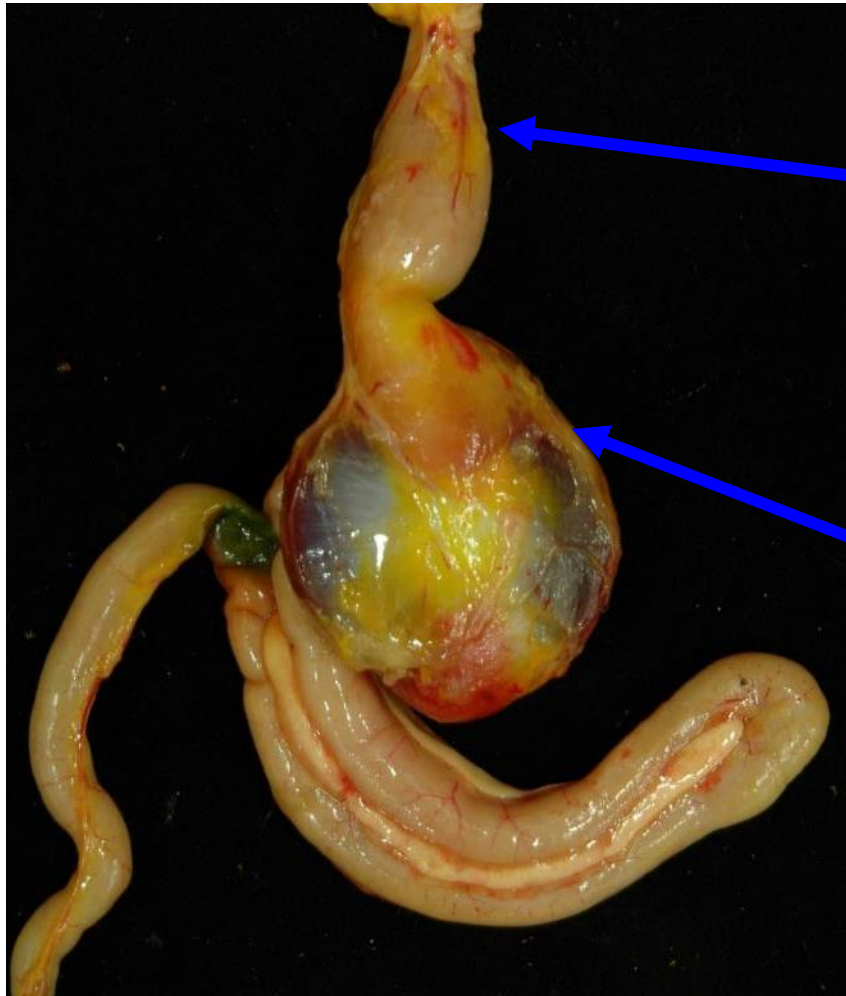
Open, examine trachea



Collect transverse section of trachea, esophagus together
Collect transverse section of crop

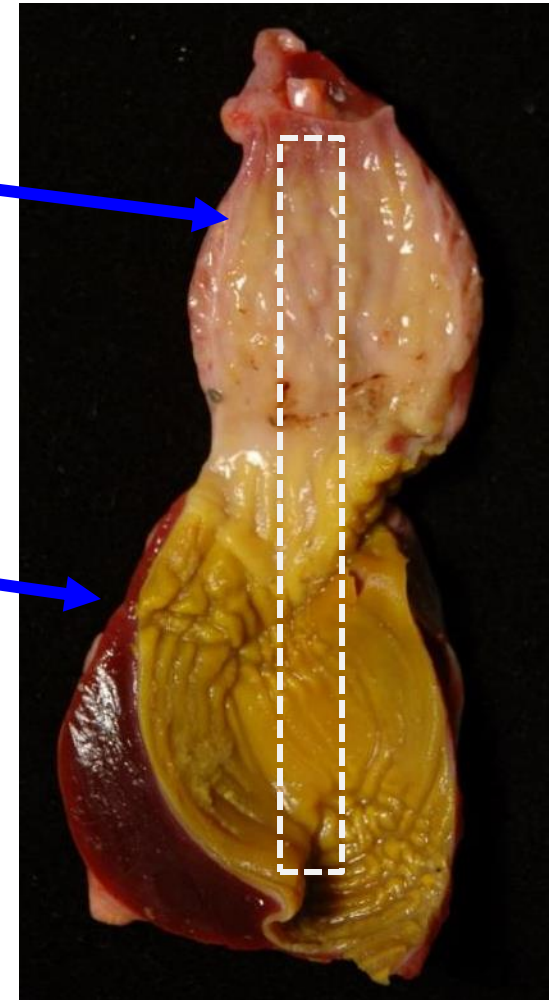


Open, examine, sample: Proventriculus, ventriculus

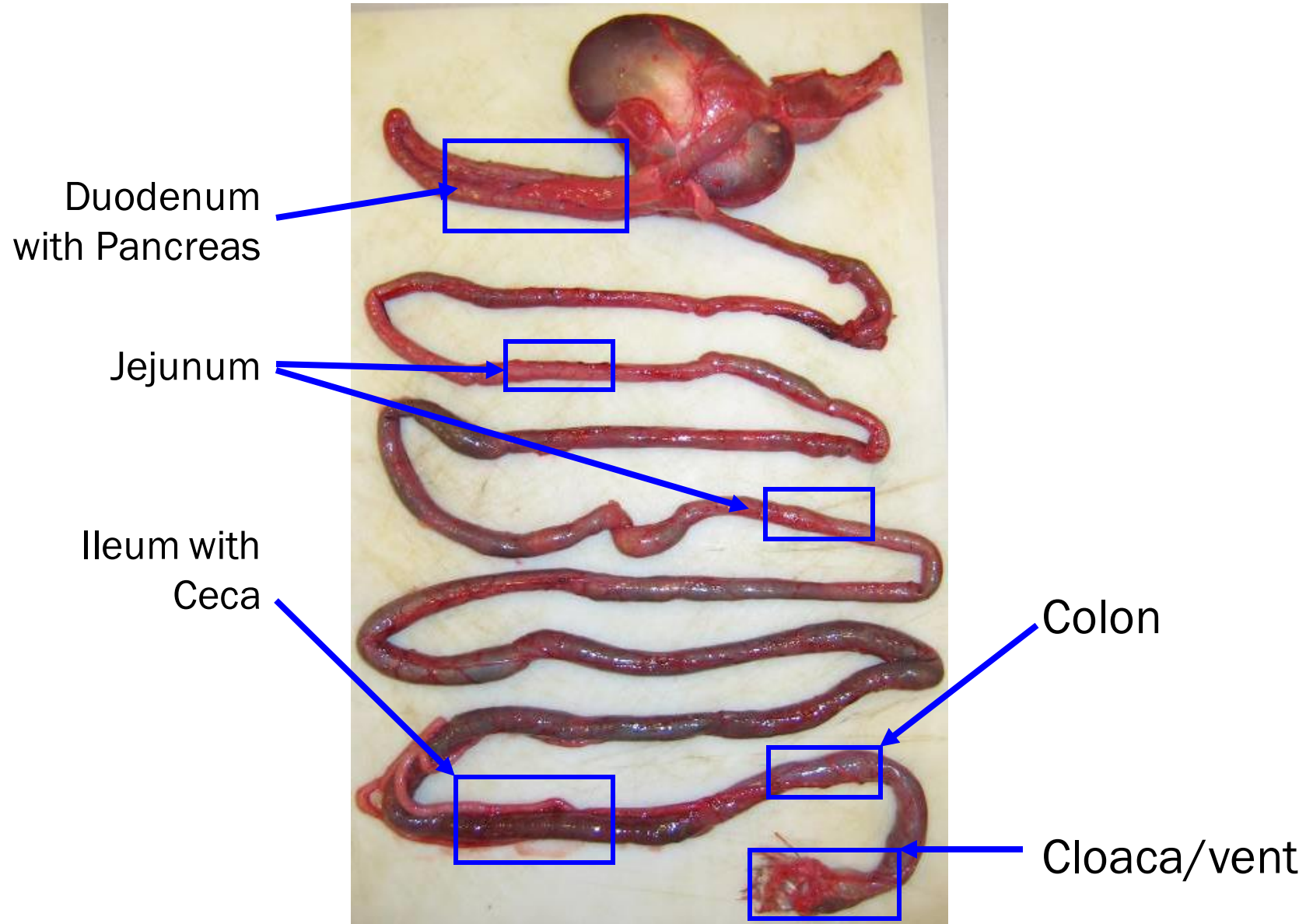


Proventriculus

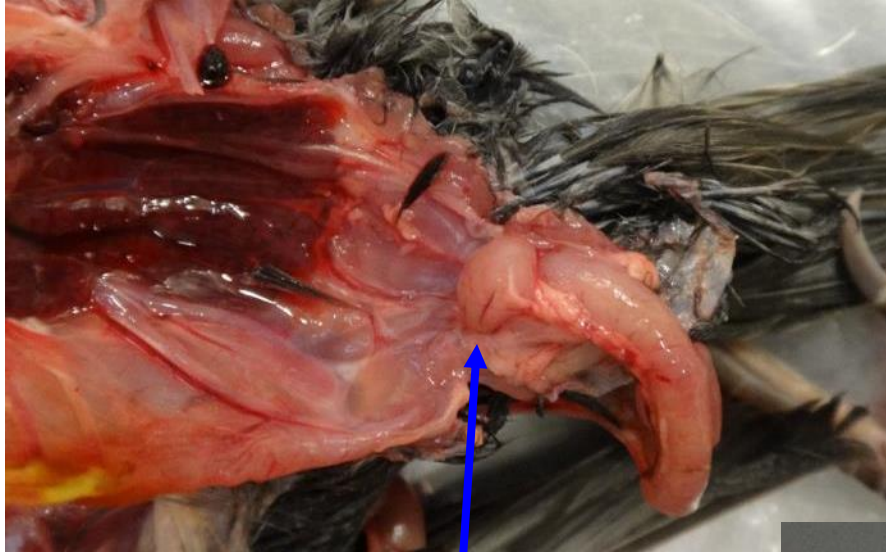
Ventriculus



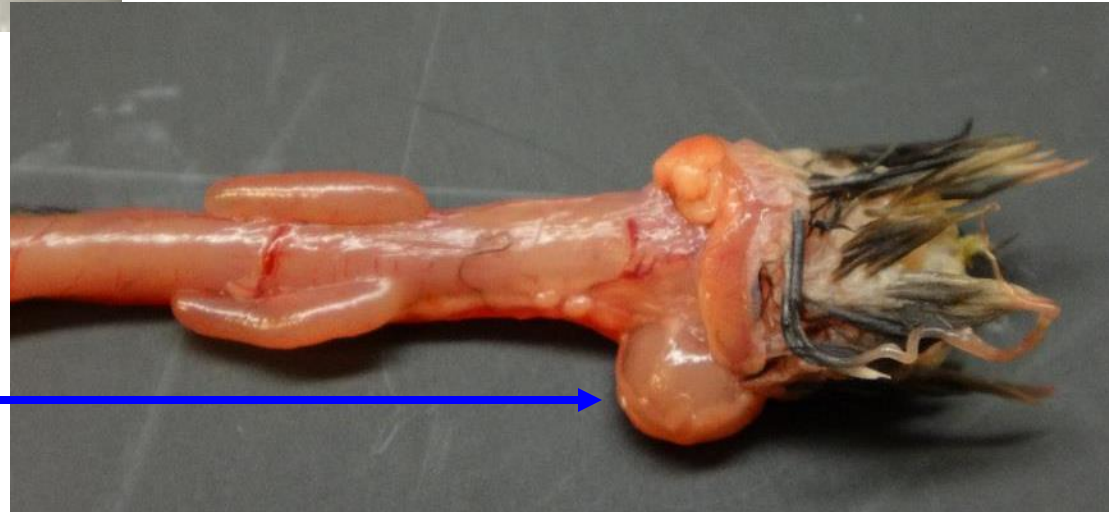
Open, examine
sample:



If present: Examine, measure, collect bursa of Fabricius with cloaca



Bursa of
Fabricius



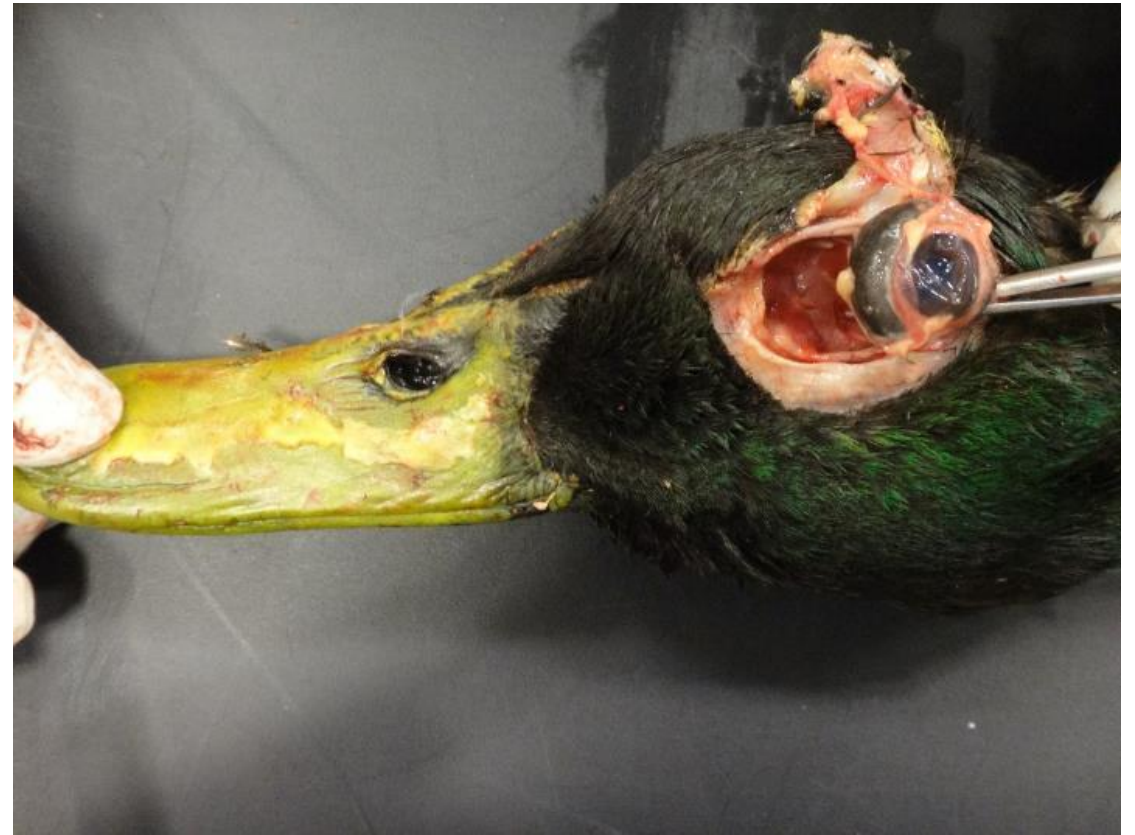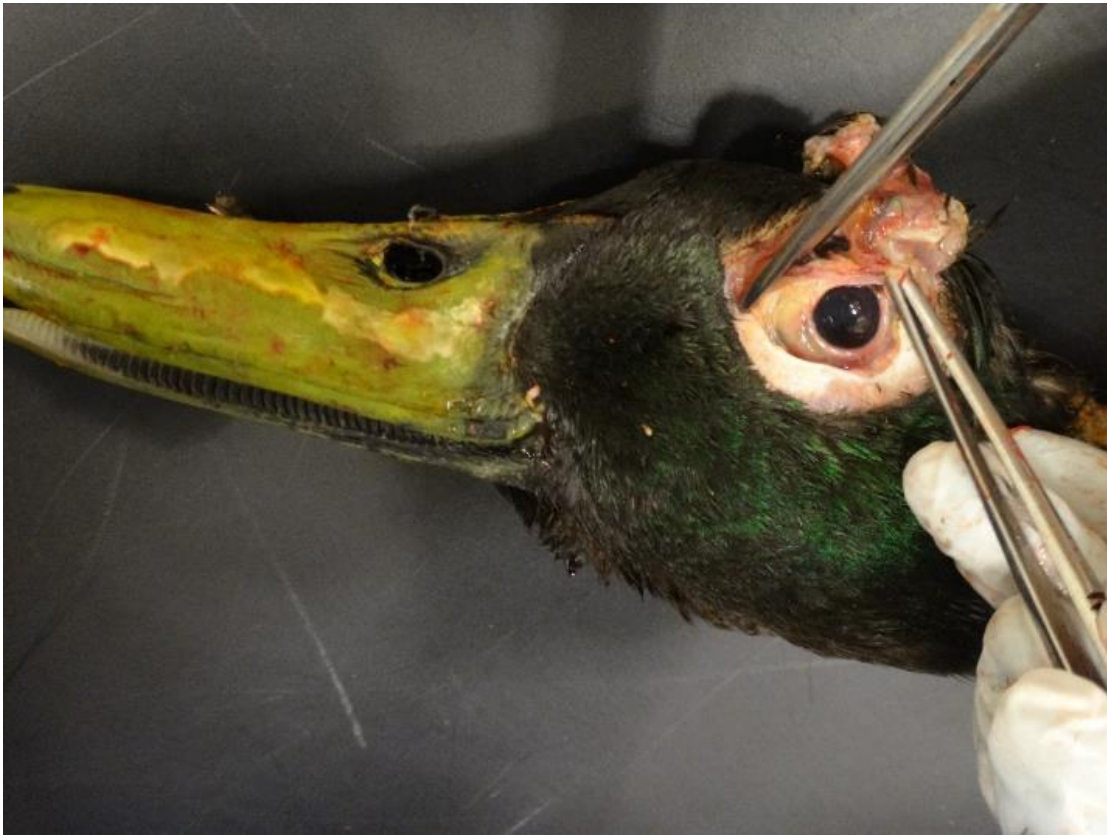CHECKPOINT 3

Internal examination part 3

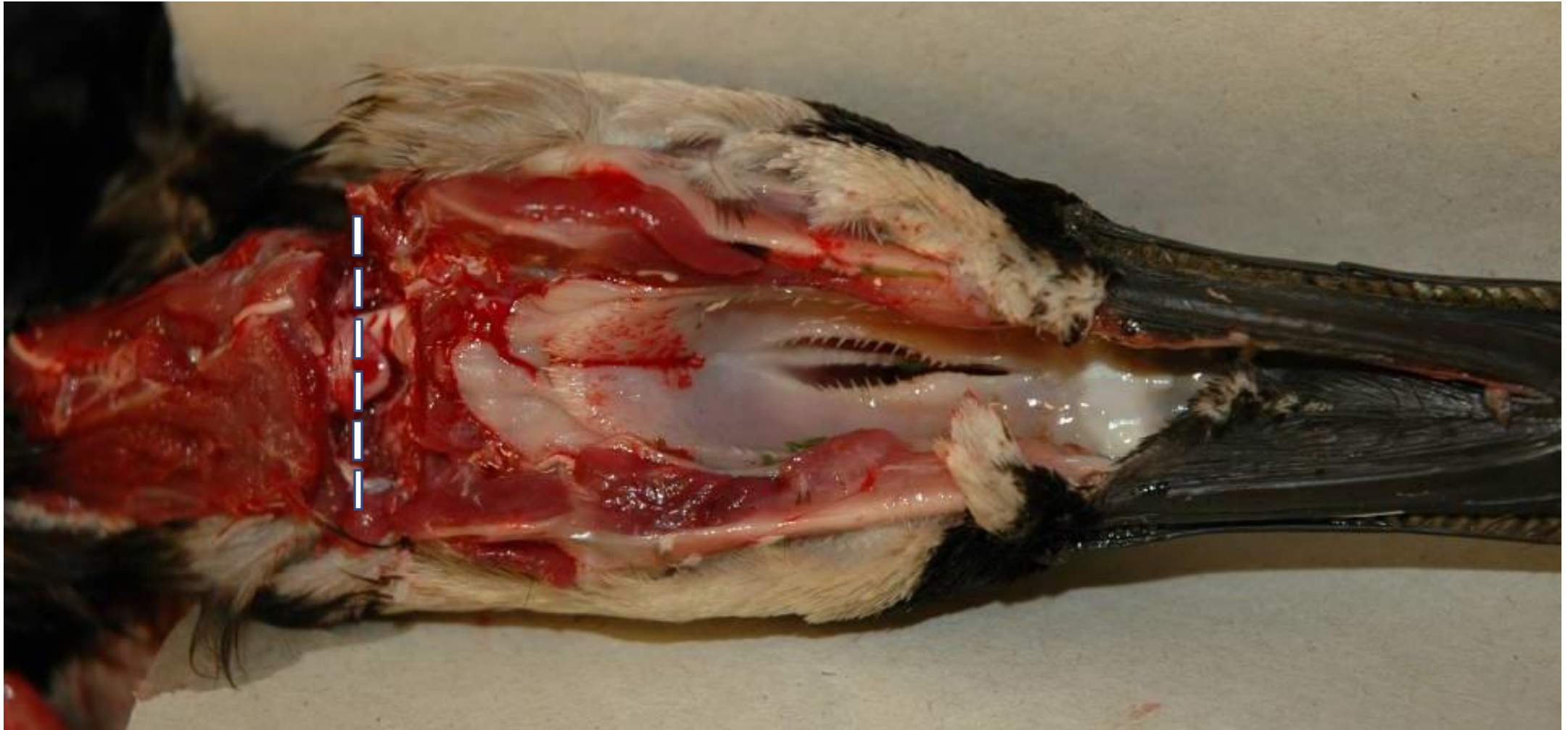- **Coelomic viscera**
 - Gastrointestinal system
 - Respiratory system
 - Urogenital systems
 - Hematopoietic tissue
- **Lesions**
- **Samples**



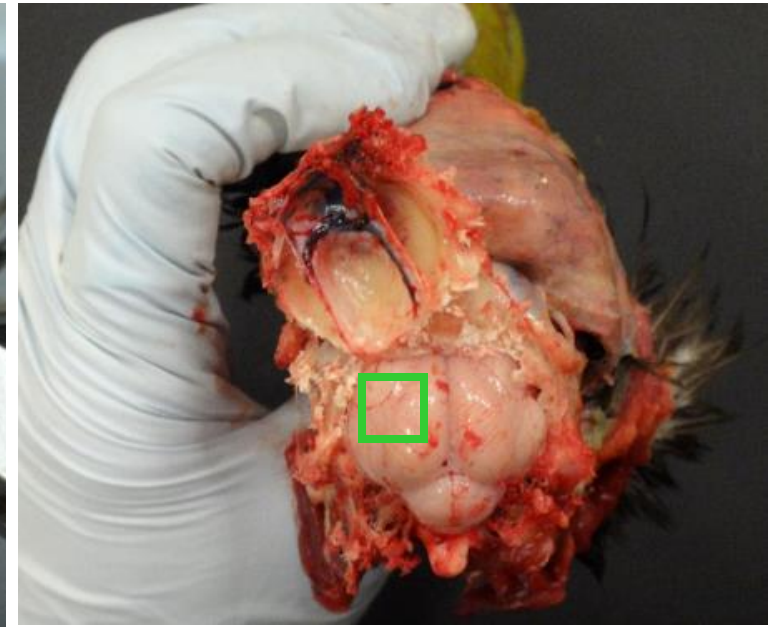
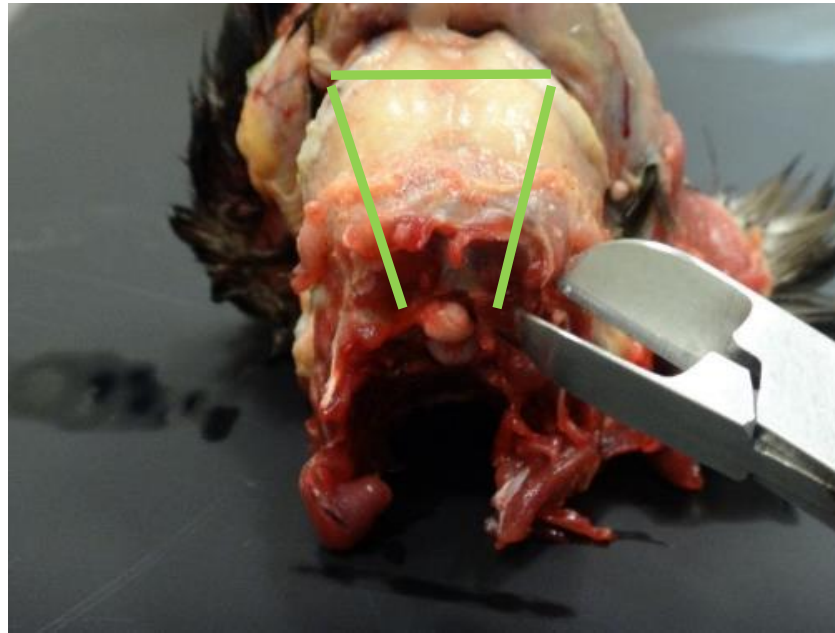
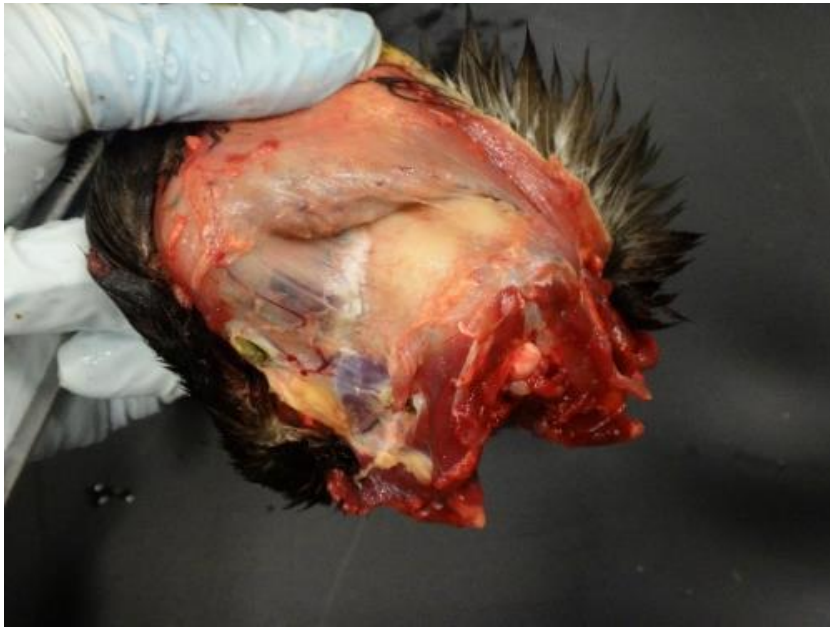Examine, remove, collect whole eye (one or both)
Examine, collect salt glands (species dependent)



Remove head at atlanto-occipital junction

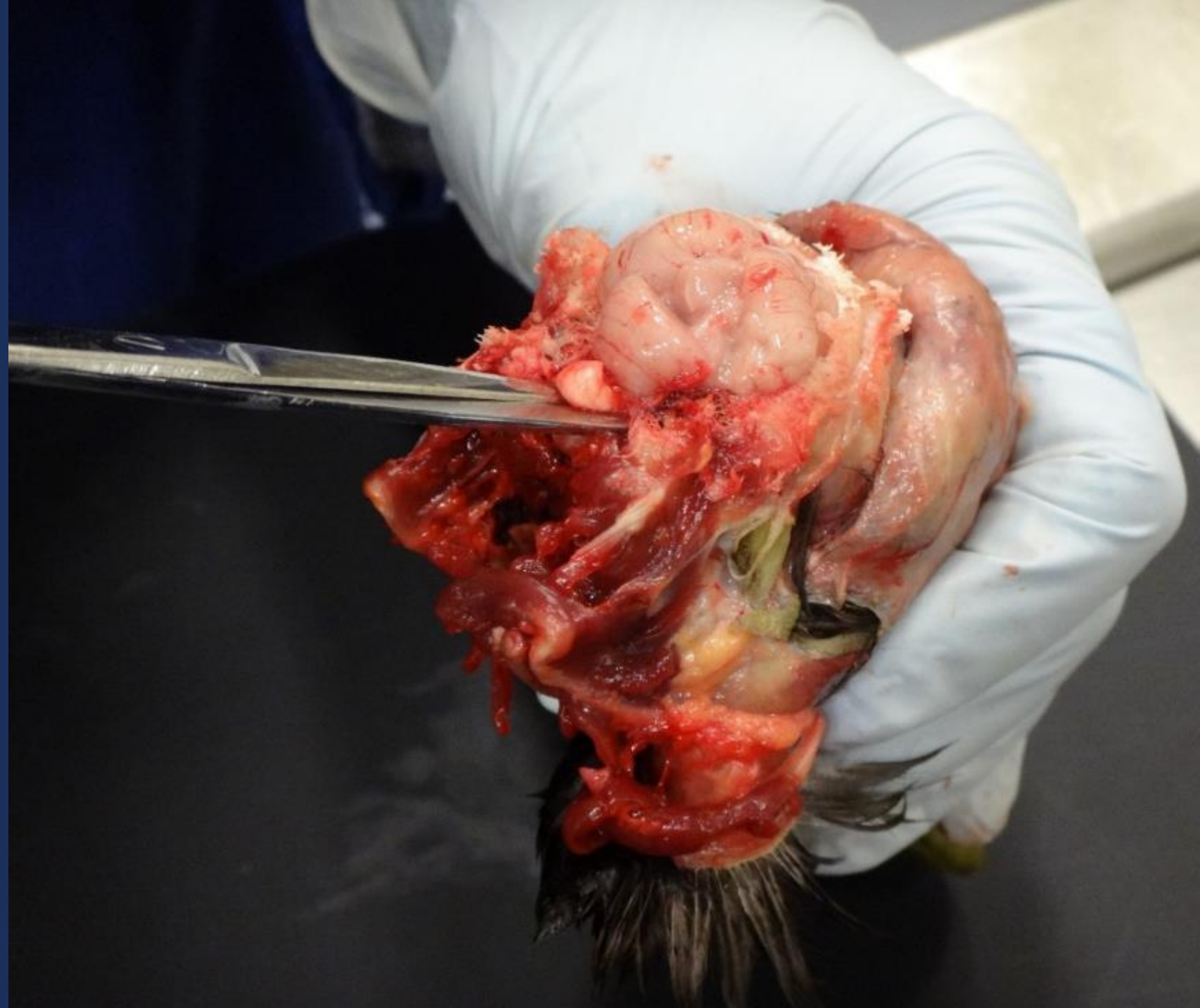

Remove skin, muscle to expose skull
Remove skull cap, visually examine meninges, brain
Collect sterile brain sample

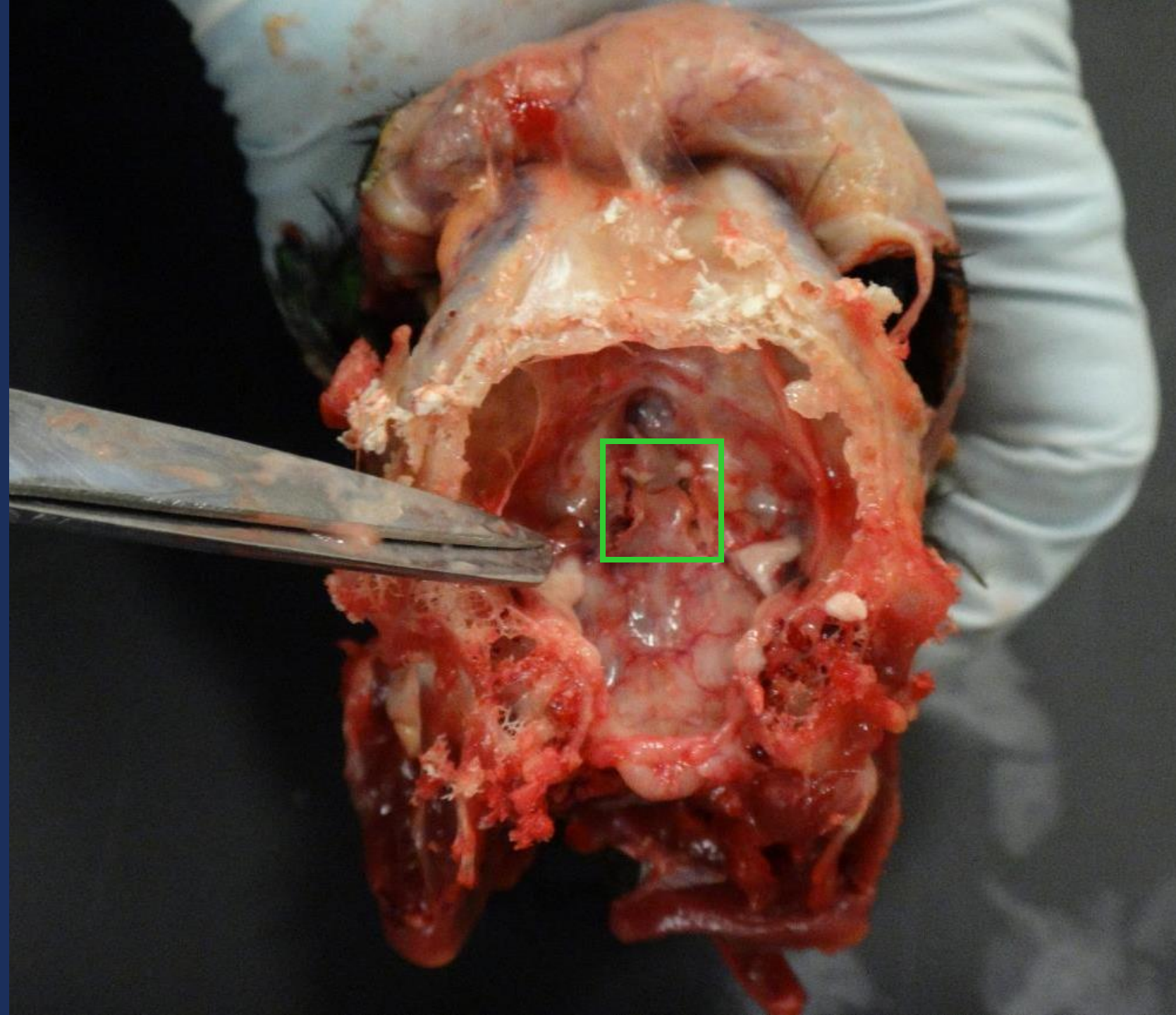


Remove brain, collect whole

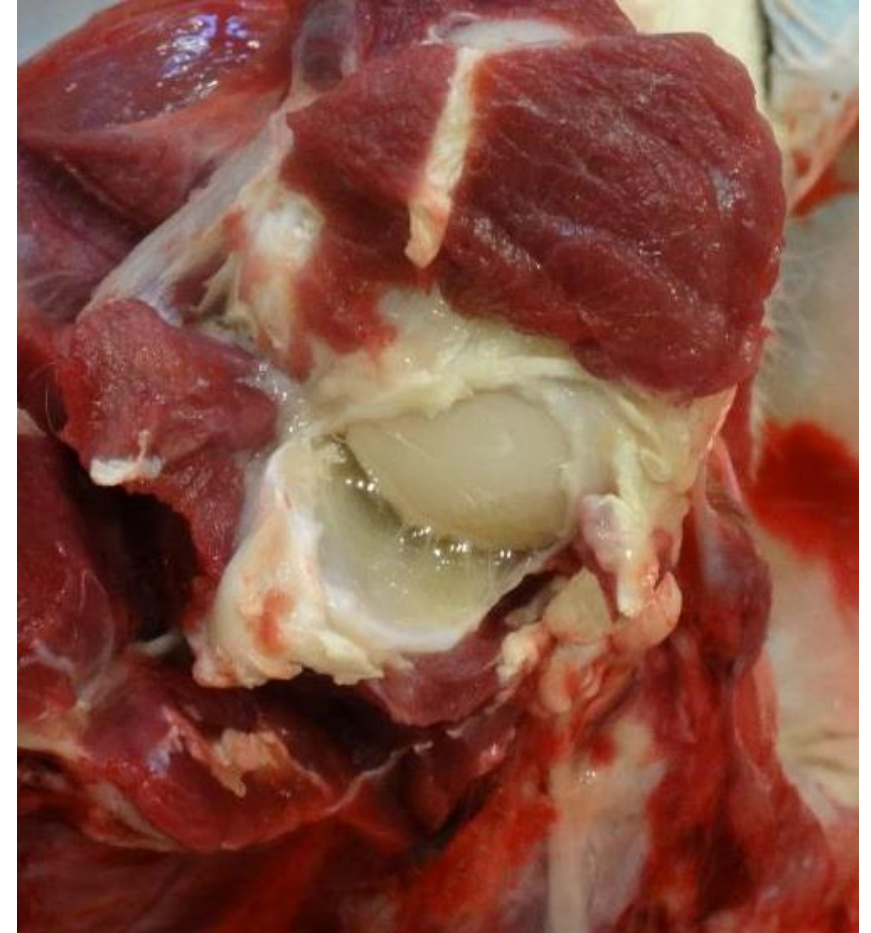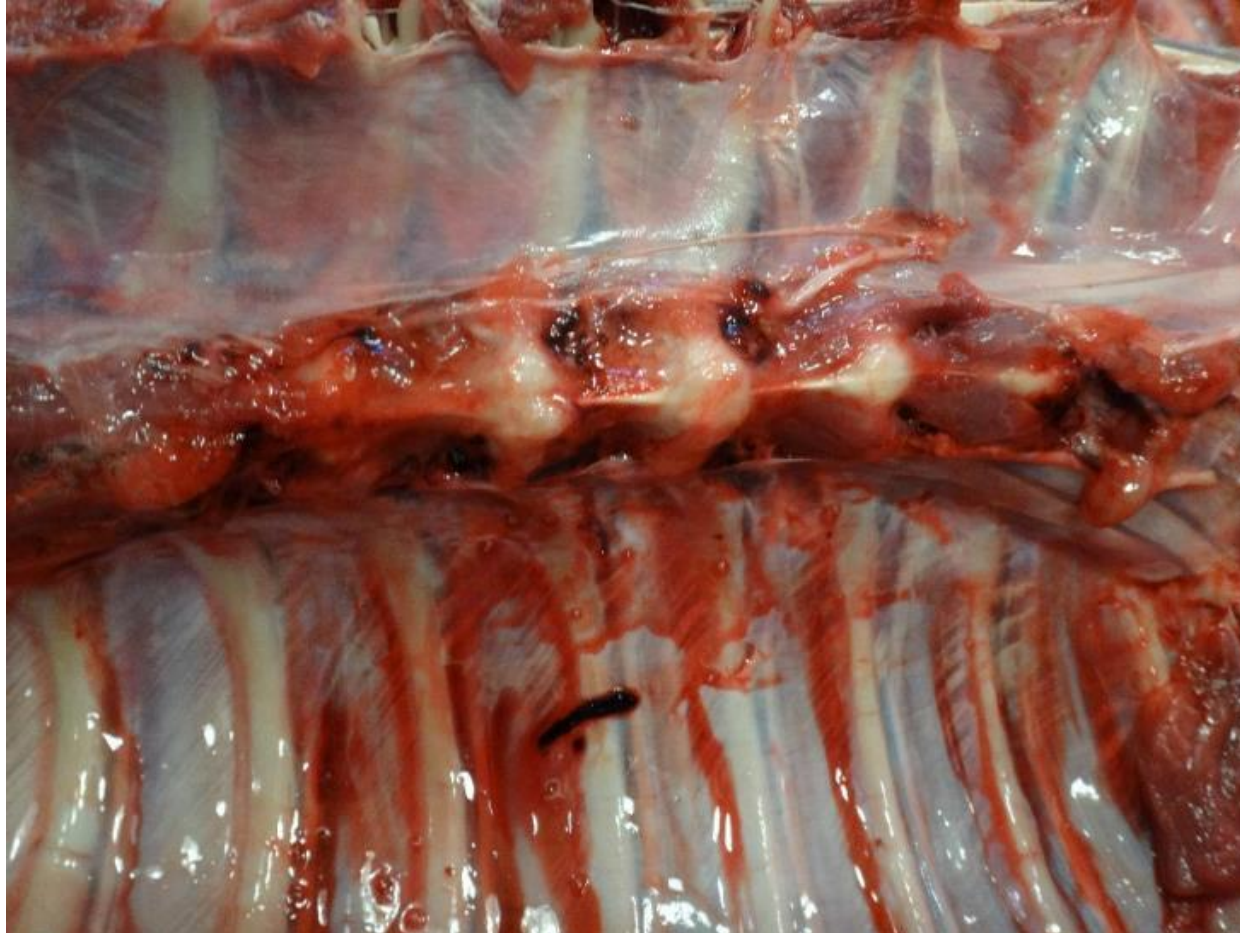Note: For small birds (head length , 2 cm), remove skull cap but leave brain in skull for formalin fixation



Examine and collect pituitary gland



- Skin carcass, assess for lesions (e.g. broken bones, hemorrhage)
- Palpate ventral surface of the spinal column, note abnormalities
- If indicated by case: open, examine, and sample any other relevant anatomic location (e.g. vertebral column, spinal cord, metatarsal joints)



CHECKPOINT 4

Internal examination part 4

- Eyes, head, brain, carcass
- Lesions
- Samples



Final Steps

Disposal of necropsy materials, carcass - **INCINERATE**

Clean equipment - **CLEAN + DISINFECT**

- Instruments – soap & water + autoclave
- Surfaces – soap & water + virkon/bleach/etc.

Samples: label, store, send to appropriate diagnostic department, ship

Tissue/sample checklists/photos

Necropsy report

Tissue examination and collection checklist

TISSUE	Sample Collection checklist:
GENERAL ex	Tissues
Ceal cavity & v	Complete
Tonsils	Swabs
Skin and nails	Rectal/cl
Subcutis	Orophary
Skeletal muscle	Blood
Peripharal nerv	Serum
Mammary gland	Blood spc
Lubricant	Blood sm
BONES & JO	Molecula
Bone marrow (f)	Brain
Bones	Kidney
Hips	Liver
Knees	Lung
Tarsi	Spleen
Shoulders	Toxicolog
Carpi	Stomach
Metacarpals	Brain
CAVITIES	Liver
Thoracic cavity	Kidney
Abdominal cav	Tissue im
PLUCK	Liver
Tongue	Lung
Thyroid/parath	Spleen
Esophagus	Genetic
Crop	Skin
Trachea	Muscle
Lungs	Parasites
Heart/Pericard	Endoparas
Aorta & other v	Ectoparas
Thymus/Lymph	Abnorma
GA = Gross	Tissue:
FF = Feces	<input type="checkbox"/>
Histo = Tissue	<input type="checkbox"/>
Cyto = Cytol	<input type="checkbox"/>
PHOTO = Photo	<input type="checkbox"/>
20/70 = Fw	<input type="checkbox"/>

Internal Examination

Musculoskeletal system (e.g. fractures, dislocations, arthritis, joint infection, muscle atrophy, trauma):

Body cavity

Cardiovascu

Respiratory

Gastrointes

Urinary syst

Reproduct

Lymphatic s

Endocrine s

Nervous sys

GROSS NECROPSY EXAMINATION

Use the spaces below to record the size, shape, color, consistency/texture of the organs examined and the location, number and distribution of any abnormal findings.

Take a ph if the exa

Wild Health Net

NECROPSY FORM

Projector: Organization:

Data recorder: Organization:

EVENT INFORMATION

Event ID:

Location of event:

Location of necropsy:

Necropsy date: Necropsy time:

Storage (prior to necropsy): Ambient Refrigerated On Ice Frozen

Multiple animal deaths?: Yes No Number of animals (if yes):

Note: If several necropsies are carried out in a multiple death event, records all the event information only once and report the event ID on the form for the next animal necropsy.

ANIMAL INFORMATION

Animal ID:

Location of death: GPS Location:

Date of death: Time of death:

Carcass recovery date: Carcass recovery time:

Carcass condition: Fresh Early Advanced Completely decomposed

Species:

Sex: Male Female Undetermined

Age: Neonate (days) Juvenile (weeks/months) Adult Geriatric

HISTORY

Suspected cause of death (circle)

Other: Euthanasia Trauma Poison/Toxin Infectious disease Other Unknown Hunting/Poaching: Snare Gunshot

Known history:



WCS Acknowledgements

Resource Created by:

Denise McAloose, VMD, Dipl ACVP

Charlotte Hollenger, DMV, Dipl ACVP

Alisa Newton, VMD, Dipl ACVP

Alice Porco, DVM, MPH

Emily Denstedt, DVM, MPH

Patricia Walsh

Ania Tomaszewicz

Supported by:

The WildHealthNet initiative was funded by the Defense Threat Reduction Agency (DTRA) Biological Threat Reduction Program (BTRP) of the U.S. Department of Defense.

